

BILATERAL MACULAR EDEMA ON A BACKGROUND OF OPTIC DISC DRUSENS

Štrofová H.¹, Jarošová A.¹, Ženišková R.²

¹ Vidente s.r.o. – private ophthalmology clinic, Prague

² Thomayer hospital – department of ophthalmology, Prague, Dr. Karel Sedláček

The authors of the study declare that no conflict of interests exists in the compilation and subsequent publication of this academic communication, and that it is not supported by any pharmaceuticals company.



MUDr. Helena Štrofová,
Vidente Vinohrady, s.r.o.
Vinohradská 176
130 00 Praha 3
h.strof@seznam.cz.

SUMMARY

In the case report, bilateral cystoid macular edema with optic disc edema on the left side in young man is described. As etiology out of the systemic diseases, we considered the hypertension. The results of the neurological examination, including the brain CT examination were physiological. The patient was examined by the internal specialist, the hypertension was treated – and it was the presumed etiology of the ophthalmologic findings. Due to the repeated worsening of the ophthalmologic findings, we searched for other etiology. Bilateral buried optic disc drusen were found by means of ultrasound. Bilateral cystoid macular edema and optic disc edema were evaluated as signs of circulatory disturbance of the posterior ciliary arteries and macular choroid caused by optic disc drusen. The antiglaucomatous treatment was started with – alpha 2 adrenergic receptors agonist – brimonidine – which increases the blood supply of the optic nerve and decreases the intraocular pressure with presumed delay of axons dysfunction.

Key words: macular edema, optic disc drusen, intraocular pressure, visual field, ultrasound

Čes. a slov. Oftal., 72, 2016, No. 1, p. 310–318

INTRODUCTION

Optic disc drusens are spherical hyaline deposits of various size, with a tendency towards calcification, deposited at various depths of the prelaminar part of the optic nerve (ON). Optic disc drusens occur in approximately 0.3 – 1% of the population, but the prevalence increases to 3.4% in persons with a family anamnesis (FA) of optic disc drusens [1, 6].

Approximately 75 – 91% of clinical cases are bilateral. Men and women are afflicted with equal frequency. The largest prevalence of the pathology is recorded in the Caucasian population [1].

The pathogenesis of optic disc drusens is not entirely clear. Drusens are deposits of mucopolysaccharides and material of a proteinic nature (amino acids, nucleic acids), concretions of calcium and sometimes also iron [1, 2, 6]. Some authors are of the opinion that they originate as a consequence of axonal degeneration of the ON or through secondary chronic obstruction of axoplasmic transport in the congested papilla of the ON [6]. Nevertheless, this is yet to be demonstrated.

In the majority of patients this concerns a chance finding in which the patient suffers no complaints. In some patients, however, blind spots occur in the visual field. Subjective symptoms are abnormalities in peripheral vision or transitional visual blackouts such as “flashing” or “greying” caused by brief episodic ischemia of the nerve. Patients do not usually complain of central loss of vision, which is generally retained. Rare cases of obnubilation are described in the literature (circulatory disorders in the region of the posterior ciliary arteries) [3, 5]. Upon perimetric examina-

tion blind spots in the visual field are often demonstrated, of the type of bundles of nerve fibres caused by ischemia in the region of the posterior ciliary arteries. The frequency of disruption of the visual field in adult patients with optic disc drusens has been reported within a range from 24% to 87%. Frequently described disruptions of the visual field incorporate enlargement of the blind stain, arcuate scotoma or peripheral scotomas. Nasal blind spots and generalised constriction of the visual field have also been described [1, 2, 6]. Standardised sonography of the eyeball (A and B scan) is a very reliable examination method thanks to the characteristic highly reflective character of optic disc drusens. A B-scan is capable of detecting deeply embedded deposits of calcium in the ON. Small solitary drusens can be identified by ultrasound (US) as hyperechogenic deposits with an acoustic shadow. Calcifications can be identified well even at lower levels of the ultrasound signal. Larger drusens are generally visible on computer tomography (CT). Drusens (especially superficial) are autofluorescent and are thus displayed as light regions on the papilla of the ON. Upon fluorescence angiography (FAG) drusens are shown as uneven hyperfluorescences, especially in the late phase. This could be useful for differentiating optic disc drusens from actual papilledema [2, 4].

Causal therapy does not exist at present for optic disc drusens. Patients with demonstrated optic disc drusens should be regularly monitored once per year – examinations of IOP, visual field and analysis of the RNFL. In the case of blind spots of the visual field in the presence of optic disc drusens, application of local anti-glaucomatous drugs is generally recommended. Progressive loss of the visual field is caused by

direct mechanical compression of the axons of the ganglion cells, circulatory disorders of the posterior ciliary arteries and subsequent ischemic changes. Reduction of IOP may alleviate this process and defer dysfunction of the axons to a certain degree. Furthermore, ocular antihypertensive drugs improve blood perfusion of the ON, which may reduce the risk of a vascular episode as a consequence of the presence of drusens. The significance of these and other prospective therapeutic modalities such as neuroprotective agents, is the subject of research [2, 5, 11]. The authors Jirásková et al. conducted decompression of the ON with disruption of the visual field and recorded a marked improvement of visual function [8, 9, 10].

Cystoid macular edema (CME) is a diffuse edema characterised by seepage into the pre-formed deeper areas of the retinal nerve layers. It is a very frequent cause of deterioration of central visual acuity or complete loss of central visual acuity. Cystoid macular edema is an accumulation of fluid in the outer plexiform layer and in the inner nuclear layer of the retina. It has a characteristic image of radially arranged cystoid areas in the region of the fovea, caused primarily by changes of the capillary wall. This leads to a breach of the haemato-retinal barrier, enabling the penetration of fluid with subsequent thickening of this region.

The diagnosis is on the basis of anamnesis, distance and close-up vision, examination on a slit lamp and biomicroscopy, fluorescence angiography and optical coherence tomography – OCT of the maculas. An image of petals concentrated around the fovea is created by fluorescence angiography.

Pathologies linked with CME – diabetes mellitus (DM), hypertension (HT), ocular pathologies – age related macular degeneration (ARMD), central and branch vein occlusion, choroidal neovascularisation, vascular malformation and tumours, inflammatory ocular pathologies, diseases of the vitreoretinal interface (epimacular membrane, vitreomacular traction syndrome), hereditary degenerative dystrophy of the retina (retinitis pigmentosa), postoperatively – following cataract surgery, after filtering anti-glaucomatous operations, following pars plana vitrectomy and other procedures, condition following laser surgery – e.g. panretinal photocoagulation, Nd-YAG capsulotomy, toxic (latanoprost, betaxolol) and radical retinopathy.

Therapy is according to cause.

A range of pharmaceuticals have been tested in the treatment of CME. It is presumed that prostaglandins are inductors of histopathological changes in CME, and as a result the use of pharmaceuticals influencing synthesis of prostaglandins is recommended. Primarily local corticoids (prednisolone) are administered, inhibiting the synthesis of arachidonic acid, which is a precursor of prostaglandins, thus suppressing inflammatory reaction. Local non-steroid antiphlogistics (indomethacin) such as cyclooxygenase inhibitors suppress the conversion of arachidonic acid into prostaglandin. Peroral corticoids and non-steroid antiphlogistics have general adverse effects, as a result of which we give priority to local preparations. Intravitreal injection of triamcinolone appears to be a promising component of treatment of macular edemas of various etiology [12].

In the literature general therapy is also recommended using carboanhydrase inhibitors – acetazolamide (500 mg \acute{a} 12 – 24 hours), hyperbaric oxygen therapy with a high oxygen concentration, or pars plana vitrectomy [17]. An effective treatment of CME is intravitreally applied anti-VEGF antibodies. It is assumed that anti-VEGF antibodies have an antiedematous effect, by suppressing the penetration of fluid from the blood vessels. Bevacizumab is a purified monoclonal antibody acting against VEGF, which binds to all its isotopes and blocks their interaction with the receptors VEGFR-1 and VEGFR-2. Bevacizumab was originally developed for use in oncology, and is approved for the treatment of metastasising colorectal carcinoma, metastasising carcinoma of the breast and metastasising non-small-cell lung carcinoma. In ophthalmology it is used in off-label therapy [14].

Ranibizumab is a fragment of humanised monoclonal antibody, which binds with strong affinity to all human isoforms of VEGF-A and prevents the bonding of VEGF-A to the receptors VEGFR-1 and VEGFR-2.

For certain conditions it is possible to utilise laser photocoagulation in order to reduce infiltration and for absorption of CME [17].

CASE REPORT

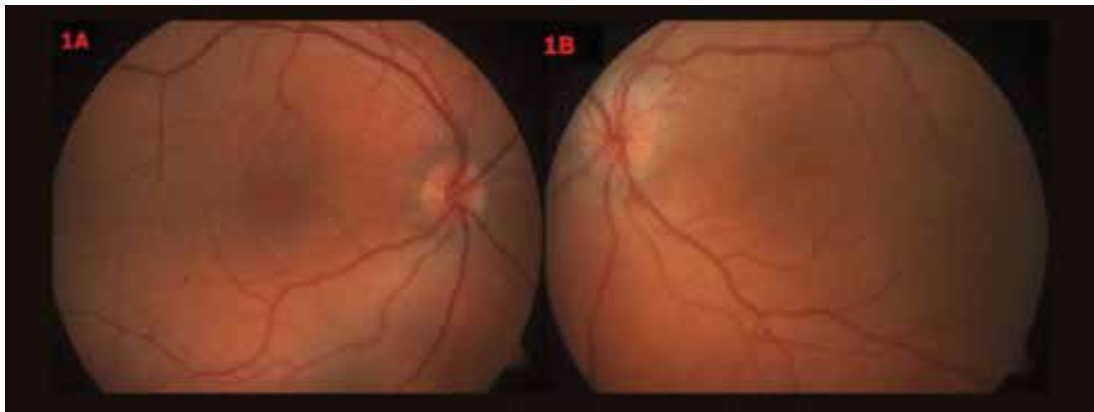At the end of November 2012 a 37 year old patient came to our centre due to deterioration of distance and close-up vision persisting for a number of months, peripheral vision without problems. He stated pronounced deterioration of vision in the last month, perceiving floating spots bilaterally, mainly in the left eye (LE). The patient does not wear glasses either for distance or close-up vision. He stated blunt-sightedness in the LE. In 2009 he underwent LASIK in both eyes. One year ago he suffered contusion of the right eye (RE) – a blow from a fist, without therapy. The patient states no other complaints. He works as an assortment consultant. Overall the patient is healthy and does not use any medicaments. In the family anamnesis he states type 2 DM and HT.

Baseline examination of patient: Vision RE (VRE): s +1.0 = -0.75/170 = 0.4, Jaeger no. (J. no.) 1 naturally (nat.). Vision LE (VLE): s +1.0 = -1.0/160 = 0.15, Jaeger no. (J. no.) 8 does not read. IOP RE/LE: 13/13 mm Hg.

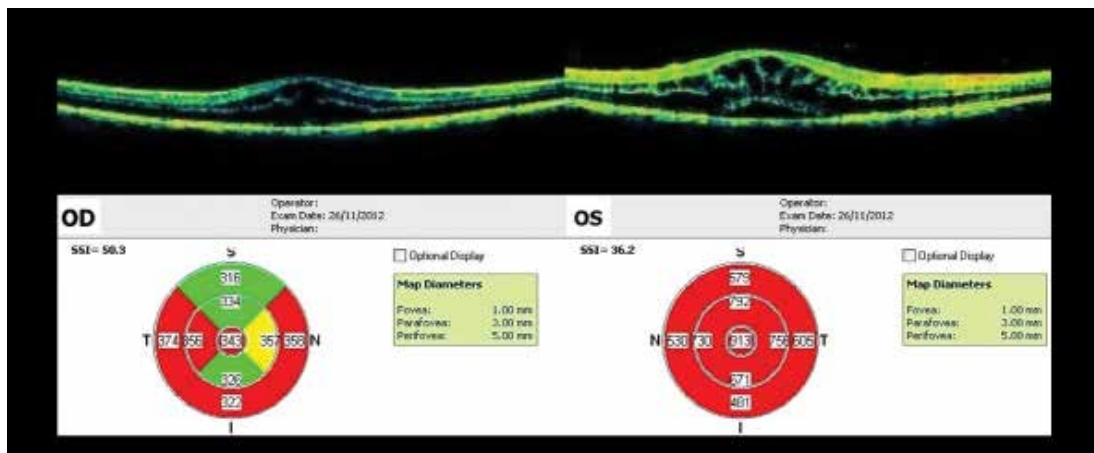
Examination of anterior segment and pupil reaction – physiological finding. Biomicroscopic examination of fundus of RE/LE: in right eye rounded papilla, bordered, pink, in left eye not sharply bordered, infiltrated, paler than right eye, slightly above niveau, parapapillary splinter haemorrhages in no. 2, bilaterally narrower arteries, harder reflexes, veins coiled, dilated, bilaterally in centre CME, in central periphery bilaterally isolated spot haemorrhages (Fig. 1).

OCT examination: OCT RE - CME, line of retinal pigment epithelium (RPE) continuous. OCT LE – flat elevation of neuroretina, cysts in intraretinal area, line of RPE continuous (Fig. 2). Blood pressure (BP) – 145/100.

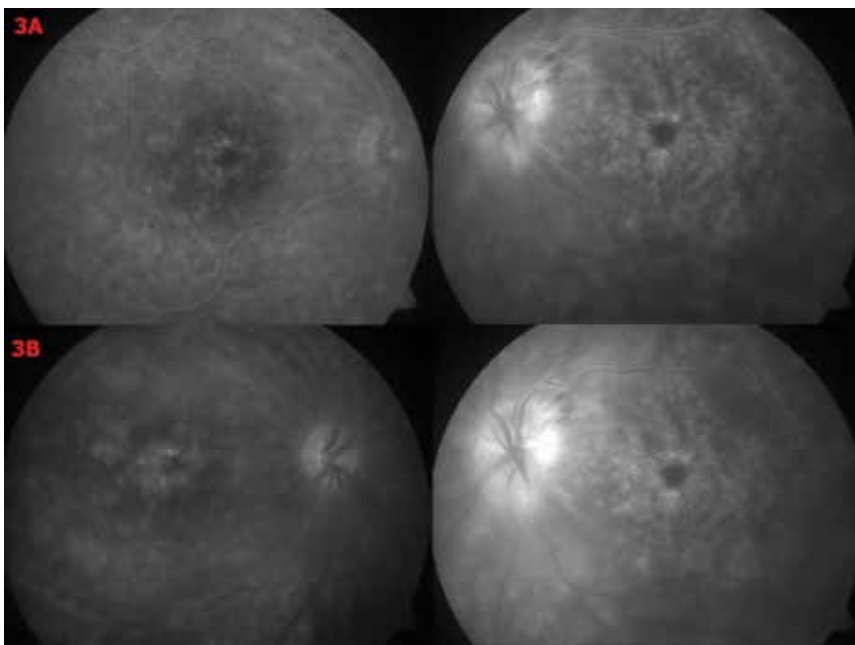
The working diagnosis was cystoid macular edema bilaterally, more in left eye (v.s. on a background of uncorrected hypertension) and oedema nervi optici lat. sin. We indicated the performance of FAG.



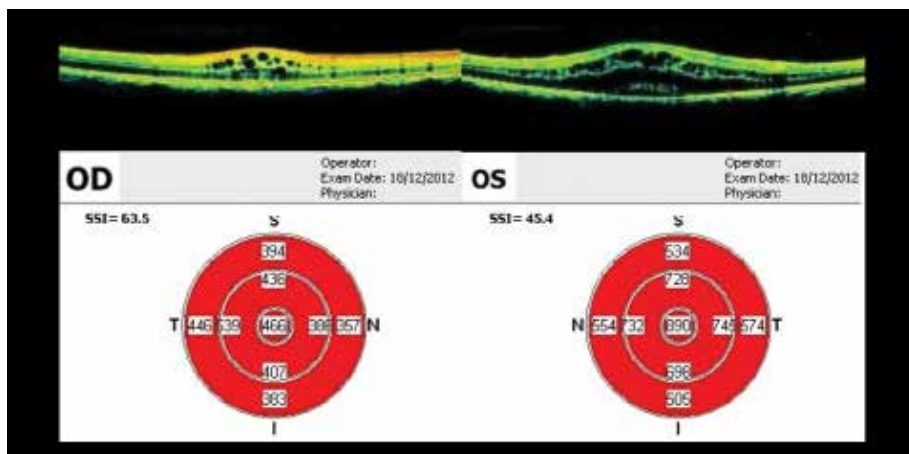
Obr. 1 Barevné fotografické snímky fundu OPL – vstupní nález
 1A – OP – papila okrouhlá, ohraničená, růžová, v centru CME,
 1B – OL – papila neostře ohraničená, prosáklá, bledší než vpravo, lehce nad niveau, parapapilárně třískovité hemoragie u č. 2, v centru CME, oboustranně užší, tvrdších reflexů, cévy vinuté, dilatované, oboustranně ve střední periférii ojediněle tečkovité hemoragie



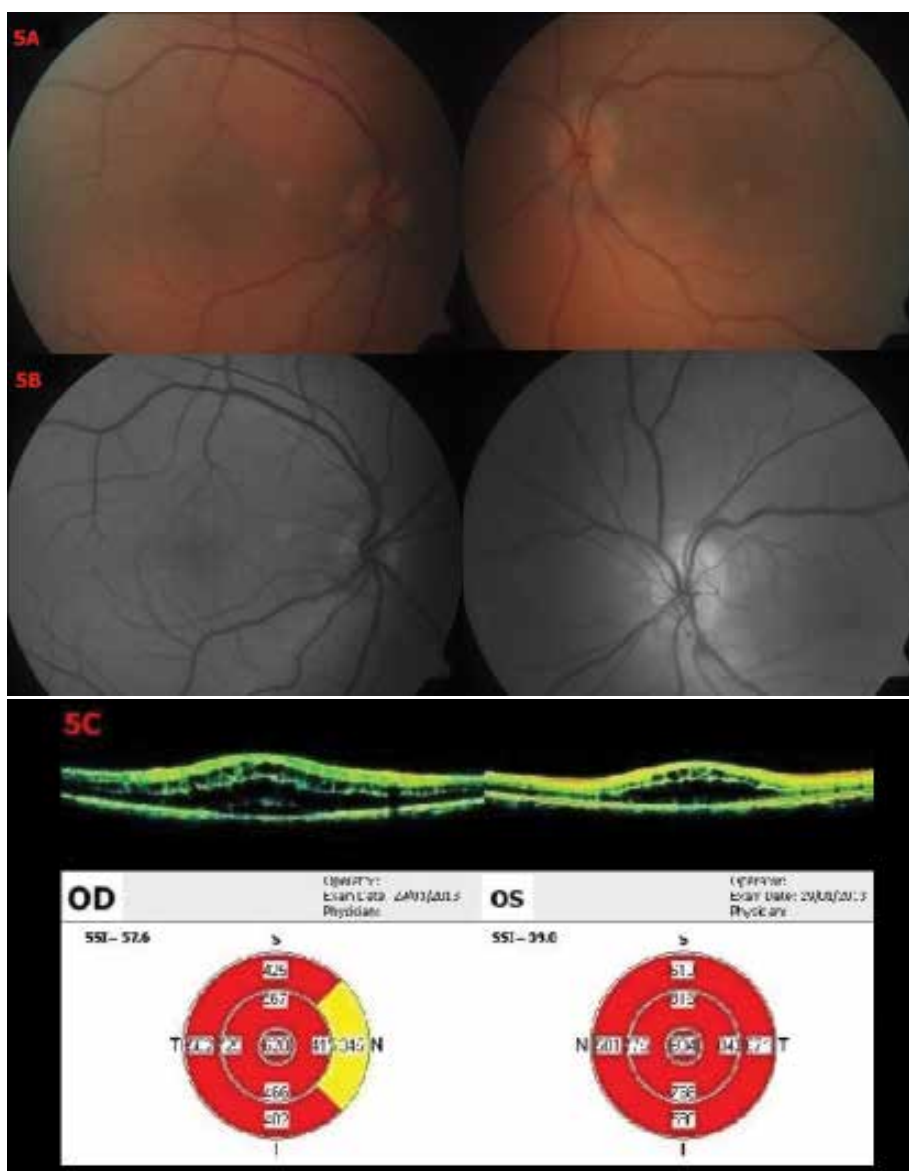
Obr. 2 OCT makul OPL – vstupní nález
 CME OPL – Oboustranně difúzní ztluštění neurosenzorické sítnice a snížení reflexivity celé sítnice v souladu s cystickou přestavbou, linie RPE kontinuální



Obr. 3 Fluorescenční angiografie OPL – vstupní nález
 3A – V makule OPL patrná hyperfluorescence v časných fázích
 3B – s časem fluorescence narůstá a cystoidní prostory se naplňují a vytváří klasický petaloidní obraz
 V periférii sítnice nalézáme drobné defekty RPE bez prosakování.
 Nález svědčí pro CME bilaterálně, bez známek přítomnosti neovaskulární membrány. Na levém amblyopickém oku je výrazná hyperfluorescence celého zrakového terče s maximem temporálně a výrazné, stupňující se prosakování barviva, které zbarvuje i přilehlou sítnici. Drobné peripapilární hemoragie temporálně nahoře doplňují nález. Jde zřejmě o obraz ischemického edému terče



Obr. 4 OCT makul OPL – 3 týdny po prvním vyšetření
Na OP je CME vyšší než při prvním vyšetření. Na OP je ve fovee 466 μ m, na OL je 890 μ m



Obr. 5 Nález 9 týdnů po prvním vyšetření
Biomikroskopické vyšetření fundu OPL – 5A – barevné snímky, 5B – red-free snímky – vlevo ubylo třískovitých hemoragií parapapilárně, jinak se nález nemění. 5C – OCT – patrná progresse nálezů na OPL

In the macula of RE/LE perceptible hyperfluorescence in early phases, with time fluorescence increases and cystoid areas are filled and form a classic petaloid image. In the periphery of the retina we find small defects of the RPE without infiltration. The finding attests to CME bilaterally, without symptoms of the presence of a neovascular membrane. In the left amblyopic eye there is pronounced hyperfluorescence of the entire disc of the optic nerve with maximum temporally, and pronounced, escalating infiltration of colouring, which also colours the adjacent retina. The finding is completed by small peripapillary haemorrhages temporally. This evidently concerns an image of ischemic edema of the disc (Fig. 3). We sent the patient to a general practitioner for a complex internal examination – mainly monitoring of BP – higher BP was repeatedly measured in outpatient care and DM was excluded. We also sent the patient for a neurological examination with regard to the finding in the left eye – papilledema of the ON. We also added samples taken for *Treponema pallidum*, *Bartonella henselae* and *Borrelia burgdorferi* in order to exclude infectious etiology. The results were negative.

The neurological examination, including CT of the brain was physiological. After confirmation of hypertension, the internist prescribed the patient a combination of an angiotensin II receptor antagonist (losartan) and diuretic (hydrochlorothiazid). DM was excluded. The ocular finding did not change.

The patient came for a follow-up examination in mid December (3 weeks after the first examination), the finding was subjectively better. Subjective examination of vision: VRE: +0.75 = 0.5p., J. no. 1 nat., VLE: 0.1p. nat., kn., J. no. 8 does not read. IOP, inding on anterior segment and on fundus is the same, on OCT examination macular edema is higher in RE than at first examination (Fig. 4). We prescribed the patient a non-steroidal anti-rheumatic drug (indomethacin) in drops 3x to RE/LE, and local corticoids (prednisolone) in drops 3x daily to RE/LE. In addition the patient was prescribed general application of a va-

soconstrictor (escin) 3x daily 2 tbl. and ascorbic acid with rutoside 2x daily 1 tbl.

At the beginning of January (6 weeks after the 1st examination) the ocular finding had not changed.

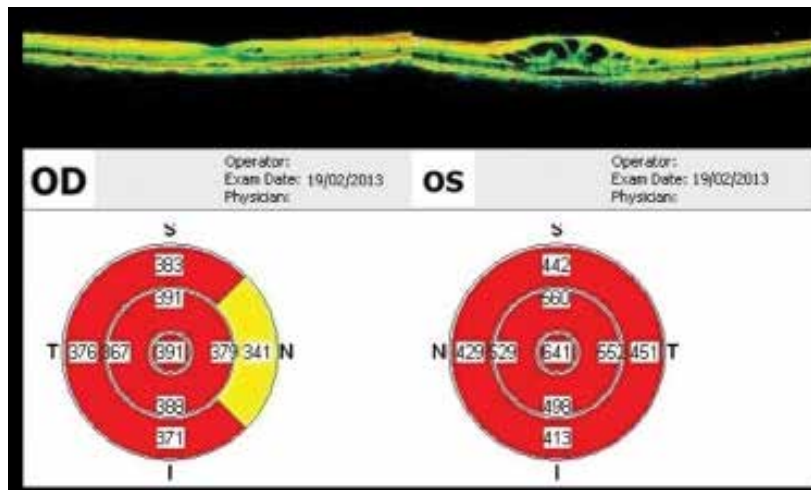
At the end of January (9 weeks after the 1st examination) the patient reported to the centre due to deterioration of vision. Vision in RE was 0.3, J. no. 7 without correction, correction does not improve, vision unchanged in LE. Decrease of parapapillary splinter haemorrhages on fundus of LE, otherwise finding unchanged. On OCT there was evident progression of the finding in RE/LE (Fig. 5). We sent the patient to the retinal consultancy at the Department of Ophthalmology at the 3rd Faculty of Medicine of Charles University in Prague and the Královské Vinohrady University Hospital in Prague for a consultation and decision on further treatment.

The patient reported to the centre with the results of the consultation, in which a diagnosis of CME on a background of uncorrected hypertension was confirmed, with persistent complaints, and according to the existing finding it was eventually recommended that intravitreal application of bevacizumab was considered. We indicated the patient for intravitreal application of bevacizumab 1.25 mg in the RE.

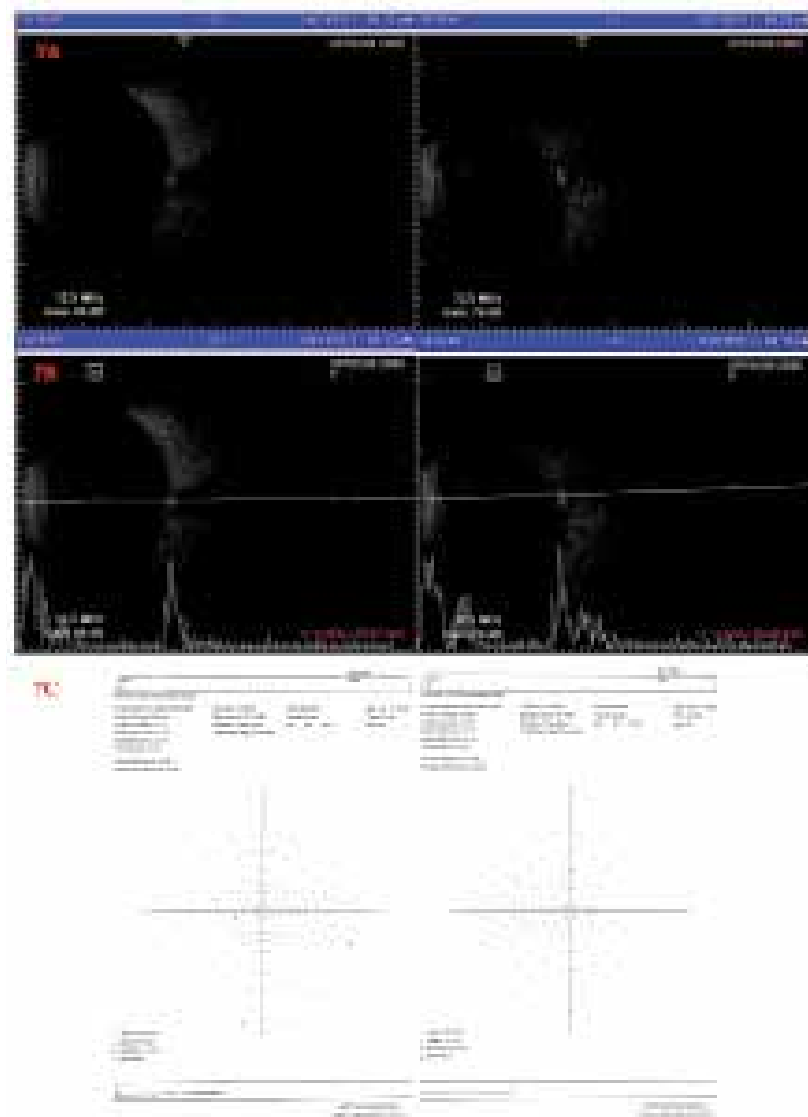
In mid February (12 weeks after the 1st examination) at the next follow-up examination the patient subjectively stated an improvement of vision. Vision in RE was 0.5p. Without correction, J. no. 3. In LE vision remained 0.1 without correction. In RE in the centre we found only coarser pigment shifts, remainders of cysts and slit ablation, in LE persistent CME but marked reduction of cysts. On OCT we found marked reduction of the finding, in RE thickness of fovea 391 μm , LE 641 μm (Fig. 6). In local therapy the stronger corticoid (prednisolone) was replaced with a weaker corticoid (fluorometholone) in drops 3x daily into RE/LE, otherwise therapy retained.

In mid March (16 weeks after the 1st examination) vision in RE had improved to 0.7, J. no. 1, LE vision still 0.1. According to the report from the internist, hypertension was on the border of compensation. In RE the finding was regressing, in LE partial haemophthalmus appeared. On OCT of RE there was disappearance of foveolar depression, slit ablation of neuroretina, thickness of fovea 340 μm . OCT of LE is with CME with pronounced cystoid alteration, ablation of neuroretina, thickness of fovea 737 μm .

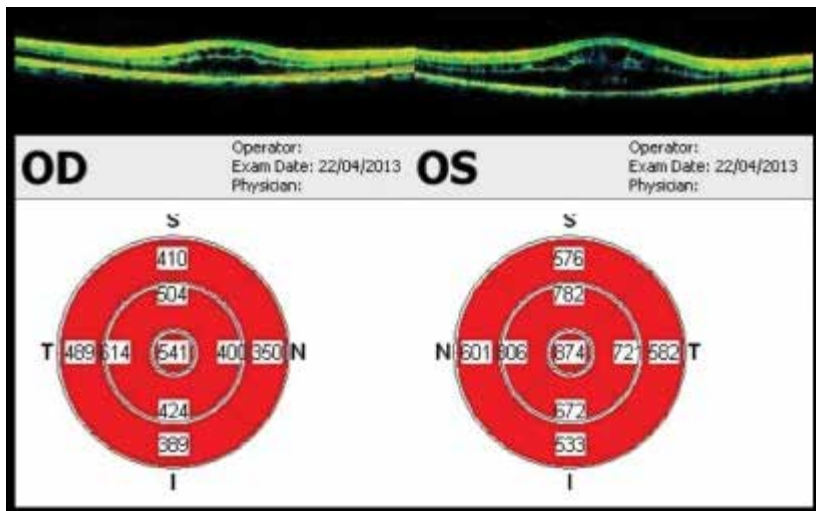
With regard to the lack of sharply bordered papilla in LE we added a sonographic examination of the eyeballs in order to exclude drusen papilla of the ON and perimeter. Immense optic disc drusens



Obr. 6 OCT makul OPL 12 týdnů po prvním vyšetření
Výrazné zlepšení nálezu, na OP ve fovee 391 μm , OL 641 μm



Obr. 7 Sonografie a perimetr OPL
7A – B scan, 7B – A i B scan – Oboustranně patrné obrovské drúzy papily ZN. 7C - perimetrické vyšetření – OP fyziologický nález, OL – ojediněle relativní skotomy, jinak fyziologický nález

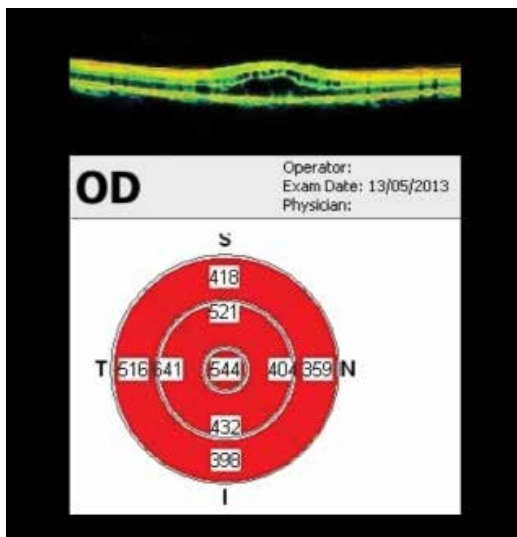


Obr. 8 OCT makul 22 týdnů od prvního vyšetření
 Progrese nálezu – výrazná cystoidní přestavba, ve fovee 541 µm na OP, na OL 874 µm. Pacient indikován k aplikaci bevacizumabu do OP

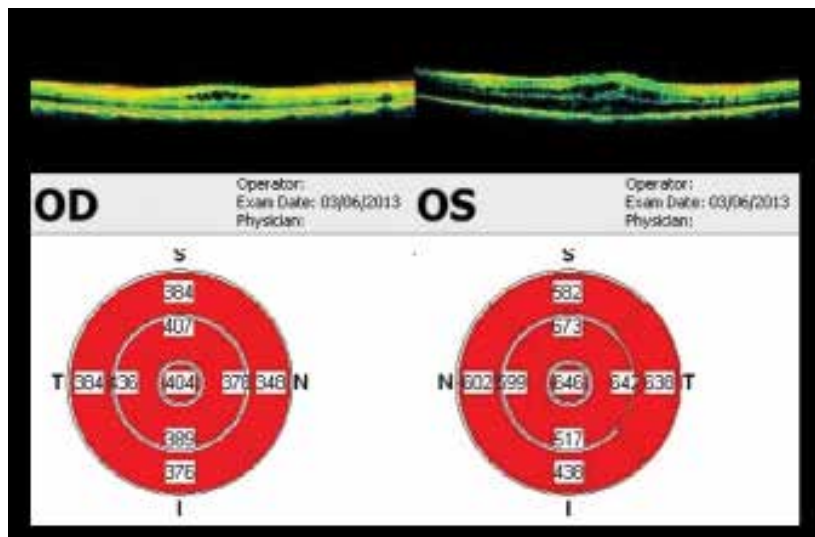
are perceptible bilaterally on sonography, the larger in LE. On a perimetric examination the finding in RE was physiological, in LE there were isolated relative scotomas, otherwise physiological (Fig. 7).

In mid April (22 weeks from the 1st examination) the patient again stated deterioration of vision. Vision in RE 0.5p. without correction, J. no. 4, in LE vision still 0.1. Again there is a progression of the finding of CME, cystoid changes bilaterally. On OCT of RE there was disappearance of foveolar depression, thickness of fovea 541 µm, cystoid edema. OCT of LE with pronounced cystoid alteration, thickness of fovea 874 µm (Fig. 8). We indicated the patient for intravitreal application of bevacizumab 1.25 mg into RE.

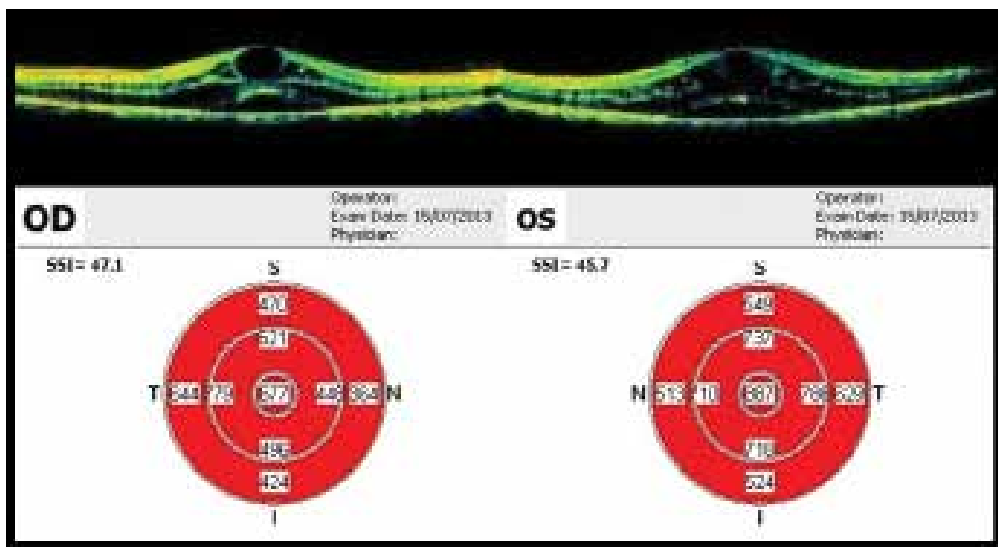
At the beginning of May (25 weeks after the 1st examination) – 3 weeks after application of bevacizumab. Subjective improvement of vision after application of bevacizumab, but in the



Obr. 9 OCT makuly OP 3 týdny po aplikaci bevacizumabu
 Ve fovee OP 544 µm, minimální reakce na bevacizumab



Obr. 10 OCT makul 29 týdnů od prvního vyšetření
 Regrese nálezu na OPL



Obr. 11 OCT makul 34 týdnů od prvního vyšetření
 Progrese nálezu – výrazná cystoidní přestavba, ve fovee 596 µm na OP, na OL 887 µm. Opět indikován k aplikaci bevacizumabu na OP

following weeks there is again a slow deterioration of vision. Vision in RE 0.5 without correction, J. no. 4. On OCT of RE – pronounced cystoid alteration, 544 μm (Fig. 9). Minimal response to application of bevacizumab, persistent CME.

At the beginning of June there was a regression of the finding (Fig. 10).

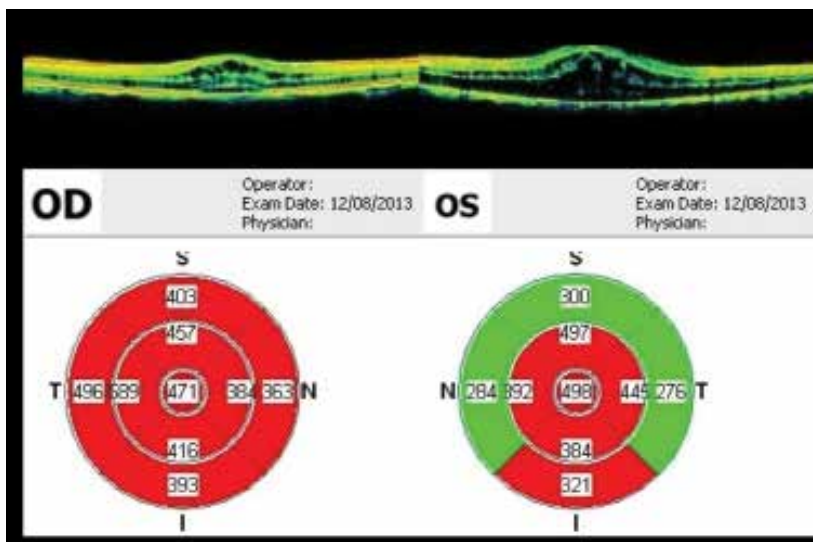
The patient then reported in mid June (34 weeks after the 1st examination) stating deterioration of vision following strenuous physical activity persisting for 3 days. Vision in RE 0.25, LE 0.1. OCT RE/LE – pronounced cystoid alteration, thickness of fovea RE 677 μm , LE 887 μm (fig. 11). Due to the pronounced progression since the last follow-up we again recommended application of bevacizumab into RE.

At the beginning of August (38 weeks after 1st examination) we found a regression of the finding. Vision in RE 0.5, J. no. 2. LE vision 0.1. OCT RE/LE – CME, thickness of fovea RE 471 μm , LE 498 μm (Fig. 12). Following consultation with the macular consultancy of the Department of Ophthalmology at the 1st Faculty of Medicine of Charles University in Prague and the General University Hospital in Prague we concluded the finding as bilateral CDE and papilledema of ON in LE on a background of optic disc drusens. The patient was prescribed an alpha-2 adrenergic receptor agonist (brimonidine) in drops 2x daily into RE/LE.

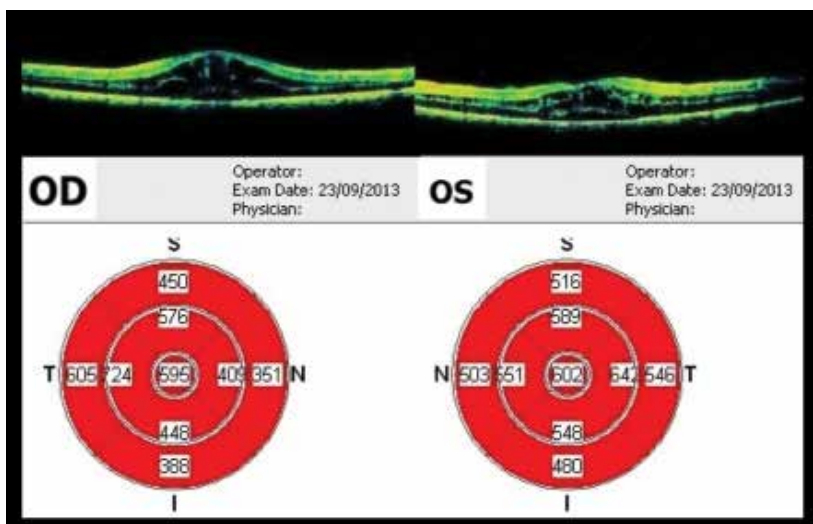
The patient reported for a follow-up examination in September (44 weeks after the 1st examination), subjectively without pronounced changes. The finding was the same, on OCT thickness of fovea RE 595 μm , LE 602 μm (Fig. 13).

The last follow-up examination was in December 2013 (57 weeks after the 1st examination), again there was progression of the finding – RE vision 0.4 nat., J. no. 8 does not read, LE 0,1 nat., J. no. 8 does not read. On OCT progression – thickness of fovea RE 638 μm , LE 862 μm (Fig. 14). It was recommended that the patient continue in local therapy with brimonidine 2x daily into RE/LE. A follow-up examination was planned after 3 months, earlier in case of deterioration. (graf 1).

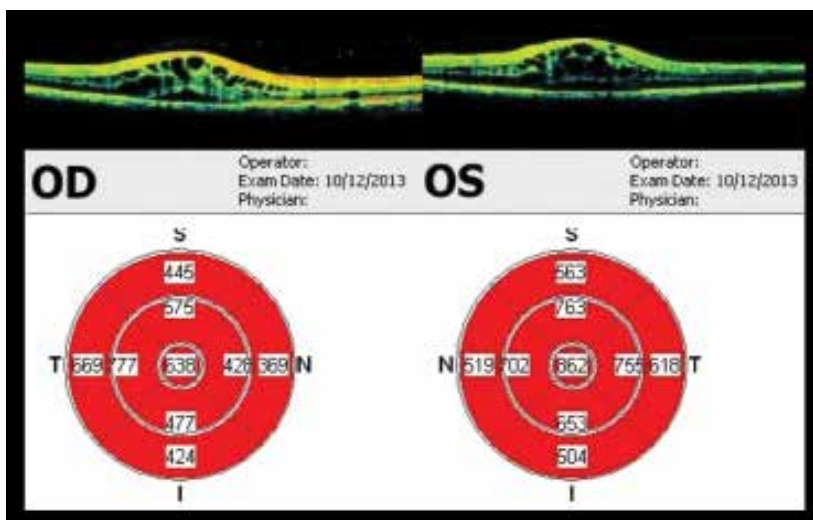
The patient is now continuing in this therapy and reporting for regular follow-up examinations. At the last follow-up vision was 0.04 nat. bilaterally, J. no. 13 does not read. The anterior segment of both eyes is pacific. On the ocular fundus of RE the papilla remains rounded, bordered, in niveau, in LE the papilla is not sharply bordered, without haemorrhages, paler, blood vessels commensurate, cystoid macular edema persists in maculas. We did not repeat a perimetric examination due to poor visual acuity. The patient is on a full invalidity pension, following a requalification course he is gaining supplementary earnings as a masseur.



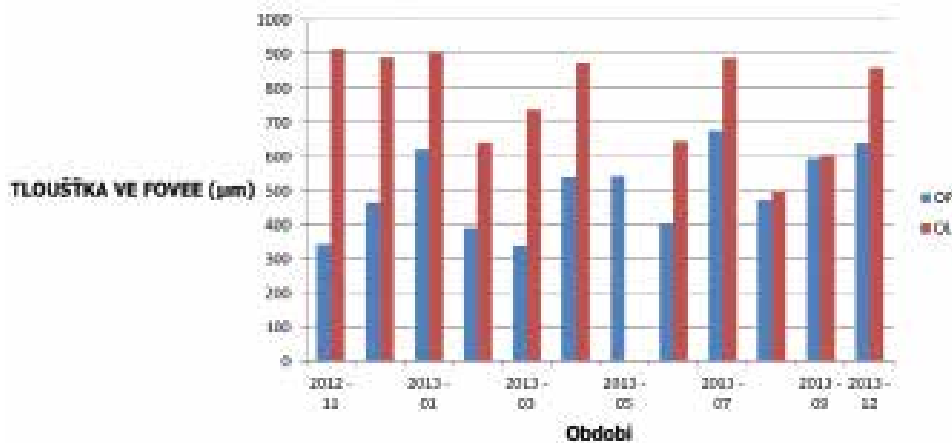
Obr. 12 OCT makul 38 týdnů od prvního vyšetření
Regrese nálezu – 3 týdny po aplikaci bevacizumabu, OP ve fovee 471 μm , OL 498 μm



Obr. 13 OCT makul 44 týdnů od prvního vyšetření
CME, na OP ve fovee 595 μm , na OL 602 μm



Obr. 14 OCT makul 57 týdnů od prvního vyšetření
Opět progrese nálezu na OPL



Graf 1 Sledování průběhu CME OPL a tloušťky ve fovee v µm

Vysvětlivky: 01/2013 – progresse nálezu – k aplikaci bevacizumabu na OP, 03/2013 – progresse na OL – parciální hemoftalmus, 4/2013 – další progresse OPL – k aplikaci bevacizumabu na OP, 07/2013 progresse na OPL – k aplikaci bevacizumabu na OP, 12/2013 – progresse na OPL OP – oko pravé, OL – oko levé, OPL – oko pravé i levé, CME – cystoidní makulární edém.

DISCUSSION

The case report describes a bilateral disorder of vision in a young patient. We determined a diagnosis of CME bilaterally with a finding of papilledema of the ON in LE primarily biomicroscopically, and also on the basis of OCT (cystoid edema) and FAG.

Of systemic pathologies we considered HT as the etiology, since the patient had repeatedly measured higher BP, in FA the patient had HT and hypersthenic habitus. We also wished to exclude type 2 DM, which the patient had in FA. We therefore recommended an internal examination and also neurological examination including CT of the brain in order to exclude intracranial hypertension. The neurological finding including brain CT was physiological. The patient was examined by an internist, HT was confirmed and treated – and this was presumed to be the etiology of the ocular finding. We recommended that the patient was applied escin as a vasoconstrictor – acting antiedematously, ascorbic acid and rutoside – in order to strengthen capillaries. We also recommended local application of corticosteroids (prednisolone) and non-steroidal antiphlogistics (indomethacin).

Due to repeated deterioration of the ocular finding we investigated the possibility of another etiology. Deeply embedded optic disc drusens were determined bilaterally using sonography. Apart from a few relative scotomas in LE, the perimeter was physiological. Due to deterioration of the finding we indicated the patient for application of bevacizumab into RE, CME responded minimally to therapy with bevacizumab.

We concluded bilateral CME and papilledema of the ON

in LE on a background of optic disc drusens. We prescribed the patient anti-glaucomatous drugs – alpha-2 adrenergic receptor agonist – brimonidine. Via the alpha-2 receptors in the ciliary body it reduces the formation of intraocular fluid and increases drainage via uveoscleral outflow. We did not want to select prostaglandins for the patient, since a side effect is described with these agents – cystoid macular edema. As a result we chose a sympathomimetic drug – brimonidine, in the case of which we expect increased blood perfusion of the ON and reduction of IOP with envisaged deferral of axon dysfunction. So far this therapy is without effect.

CONCLUSION

Optic disc drusens appear in 0.3 – 1 % of the population and are bilateral in approximately 75 – 91 % of patients.

Deeply embedded and invisible optic disc drusens may cause circulatory disorders of the posterior ciliary arteries, which may be manifested not only in circulatory but primarily in ischemic disorders of the optic nerve, as well as circulatory disorders in the macula and CME.

Thanks to Dr. Petra Svozilová from the Department of Ophthalmology at the 1st Faculty of Medicine of Charles University in Prague and the General University Hospital in Prague for professional consultation.

The pictorial documentation and data was obtained at the department of ophthalmology at Thomayer hospital – thank you.

LITERATURE

- Aumiller, M. S.:** Optic disc drusen: Complications and management. *Optometry – Journal of the American Optometric Association*. January 2007, vol. 78, no. 1, 10–16.
- Auw-Haedrich, C., Staubach, F. Witschel, H.:** Optic Disk Drusen. *Survey of Ophthalmology*, November 2002, vol. 47, no. 6, 515–532.
- Baget-Bernaldiz, M., Soler, L. N., Romero-Aroca, P.:** Optical coherence tomography study in tamoxifen maculopathy. *Archivos de la Sociedad Española de Oftalmología* [online]. 2008, vol. 83, iss.
- Dostupné z** <<http://www.ncbi.nlm.nih.gov/pubmed/18855282>>.
- Baráková, D.:** Echografie v oftalmologii. 1. vyd. Praha: Professional Publishing, 2002. 150 s. ISBN 8086419150.
- Davis, P. L., Jay, W. M.:** Optic nerve head drusen. *Seminars in Ophthalmology*,

- December 2003; vol. 18, no. 4: 222–242.
6. **Grippo, T. M., Rogers, S. W., Tsai, J. C., et al.:** Optic Disc Drusen: Practical implications and management. *Glaucoma today*, January – February 2012: 19–24.
 7. **Hauptvogelová, M. – Šustykevičová, Z.:** Non-arteritická predná ischemická optická neuropatia pri drúzach zrakového nervu. *Česká a slovenská oftalmologie*, 2010, vol. 66, no. 2, s. 184–187.
 8. **Jirásková, N., Rozsival, P.:** Dekomprese obalu zrakového nervu. *Česká a slovenská oftalmologie*, 1995, vol. 51, 254–257.
 9. **Jirásková, N., Rozsival, P.:** Dekomprese obalu zrakového nervu – výsledky u prvních 37 operovaných očí. *Čes a slov Oftalmol*, 1996, vol. 52, no. 5: 297–308.
 10. **Jirásková, N., Rozsival, P.:** Výsledky 62 dekompresí obalu zrakového nervu. *Čes a slov Oftalmol*, 1999; vol. 55, no. 3: 136–144.
 11. **Kanski, J. J.:** *Ophthalmology: Clinical Signs ad Differential Diagnosis*. 5th edition. Mosby International Limited, 2007. 485 s. ISBN 0-7234-3121-3.
 12. **Kuchynka, P., et al.:** *Oční lékařství*. 1.vyd. Praha: Grada, 2007. 768 s. ISBN 978-80-247-1163-8.
 13. **Matušková, V., Vysloužilová, D.:** Možnost léčby oboustranného makulárního edému bez anti VEGF léčby. *Čes a slov Oftalmol*, 2010; vol. 66, no. 1: 30–35.
 14. **Studička, J.:** Indikace Avastinu v oftalmologii. *Čes a slov Oftalmol*, 2010; vol. 66, no. 5: 229–233.
 15. **Suelves, A. M., Francés-Munoz, E., Gallego-Pinazo, R., et al.:** Central serous papillopathy by optic nerve head drusen. *Clinical Ophthalmology*, November 2010; vol. 25, no. 4: 1379–1382.
 16. **Tan, C. S., Teoh, S. C., CHan, D. P., et al.:** Dengue retinopathy manifesting with bilateral vasculitis and macular oedema. *Eye*, June 2007; vol. 21, no. 6: 875–877.
 17. **Tryfon, G. R., Marilita, M. M.:** Cystoid macular edema. *Clinical Ophthalmology*, December 2008; vol. 2, no. 4: 919–930.