

# REFRACTIVE SURGERY IN CHILDREN WITH MYOPIC ANISOMETROPIA AND AMBLYOPIA IN COMPARISON WITH CONVENTIONAL TREATMENT BY CONTACT LENSES

## Summary

Our study evaluated the visual and refractive results of LASEK and anterior chamber phakic intraocular lens (pIOL) implantation performed for high myopic anisometropia with amblyopia and contact lens intolerance in children compared with conventional treatment by contact lenses.

Forty-three patients (Group A) aged 3 to 7 years (mean, 5,6 years) with high myopic anisometropia and amblyopia had performed multizonal LASEK (27 eyes) or pIOL Verisyse implantation (16 eyes) on the more myopic eye in general anesthesia. Surgery was followed by patching of the dominant eye. Postoperative visual and refractive outcomes were analyzed and all children had minimally two years follow-up after procedure. Refractive surgical data were reported in standard format to describe safety, efficacy, predictability and stability of the procedure. This Group A of 43 children was compared with control Group B of 37 children (mean age 5,4 years), in whom myopic anisometropia and amblyopia were treated conventionally by contact lenses (CL) and patching of the dominant eye. Visual acuity (VA) and binocular vision (BV) outcome were analyzed and compared in both groups.

The mean preoperative spherical equivalent (SE) cycloplegic refraction in Group A was  $-9,45 \pm 2,47$  diopters (D) (range  $-6.0$  to  $-18.25$  D) and the mean postoperative SE  $-1,48 \pm 1,13$  D (range  $+0,75$  to  $-2,25$  D). The mean preop. decimal uncorrected visual acuity (UCVA)  $0,023 \pm 0,017$  increased to  $0,46 \pm 0,18$ . The mean preop. decimal best-corrected visual acuity (BCVA) in Group A was  $0,28 \pm 0,22$  and changed to  $0,78 \pm 0,19$  by 2 years after surgery. The mean BCVA in Group B was  $0,23 \pm 0,19$ , at start of CL correction and amblyopia therapy, and improved to  $0,42 \pm 0,15$  after two years. The mean BCVA at final examination was significantly better in Group A ( $P < 0,05$ ). Binocular vision improvement expressed by the proportions of subjects gained fusion and stereopsis, was overall better in Group A (81 %) than in Group B (33 %), ( $P < 0,05$ ). There were no complications after surgery.

Refractive surgery in children, multizonal LASEK and pIOL Verisyse implantation, are effective and safe methods for correction of high myopic anisometropia, and has an important role in the treatment of amblyopia in children when contact lens intolerance. Visual acuity and binocular vision outcomes were better in children who received permanent surgical correction of anisometropia, than in children conventionally treated by contact lenses.

**Key words:** myopic anisometropia, amblyopia, children, laser subepithelial keratomileusis (LASEK), anterior chamber phakic intraocular lenses (AC pIOL), binocular vision

Čes. a slov. Oftal., 72, 2016, No. 2, p. 12–19

## INTRODUCTION

The traditional conservative method of treating myopic anisometropia and amblyopia for children of school age is full correction of the spherical and cylindrical component of the refractive error using glasses or contact lenses, or a combination thereof, and above all adequate pleoptic therapy with modulated occlusion of the dominant eye.

Higher myopic anisometropia is a frequent cause of amblyopia, although according to our experiences it can be better influenced by therapy than amblyopia in the case of hypermetropic anisometropia. In the case of a difference higher than 5 to 6 dioptres, binocular tolerance of full glasses correction is sometimes problematic, despite the fact that in childhood age adaptability is substantially higher than in adulthood (31).

A quality therapeutic alternative of optical correction in the case of higher anisometropia is contact lenses. The advantages of contact lenses are above all: insignificant peak distance of fracture areas from the cornea, neutral prismatic effect upon lateral gaze, absence of anisophoria, unlimited visual field and minimal aniseikonia in anisometropia. Upon testing of contrast sensitivity in higher myopia, better results were obtained upon correction by contact lenses than glasses lenses (12). However, when determining a diagnosis of high myopic anisometropia with amblyopia in pre-school children, we always begin with a full value of glasses correction and total occlusion of the dominant eye. Nevertheless, for the development of binocular vision it is subsequently necessary to continue with "reduced partial occlusion", in which occlusion of the dominant eye is applied for a period of maximum 50% of the child's waking hours. If

Autrata R.<sup>1</sup>, Krejčířová I.<sup>1</sup>,  
Griščířková L.<sup>1</sup>, Doležel Z.<sup>2</sup>

<sup>1</sup>Children's Ophthalmology Clinic,  
Faculty of Medicine, Masaryk University  
and University Hospital Brno,  
head: prof. MUDr. Rudolf Autrata,  
CSc.,MBA

<sup>2</sup>Paediatric clinic, Faculty of Medicine,  
Masaryk University and University  
Hospital Brno,  
head: prof. MUDr. Zdeněk Doležel, CSc.

Supported by grant MZ ČR-RVO  
(FNBr.65269705) no. 12110-5/2011 IGA  
MZ ČR.

*The authors of the study declare that no conflict of interest exists in the compilation, theme and subsequent publication of this professional communication, and that it is not supported by any pharmaceuticals company.*



Prof. MUDr. Rudolf Autrata, CSc., MBA  
přednosta Dětské oční kliniky LF MU  
a FN Brno  
Černopolní 9  
613 00 Brno  
rautrata@fnbrno.cz

the child does not tolerate full value binocular glasses correction, we attempt the application of contact lenses. In the case of intolerance of contact lenses it is possible to use methods of refractive surgery, such as photorefractive keratometry (PRK), laser subepithelial keratomileusis (LASEK), laser assisted in situ keratomileusis (LASIK) and implantation of a phakic intraocular lens (pIOL). A number of Czech and foreign publications present satisfactory results of refractive surgery on paediatric patients (1-5, 9, 24, 25, 28).

Davidorf (13) states a possible division of indications for the use of refractive surgery methods on children and adolescents into 3 categories: obligatory, functional and elective. The obligatory category may include children aged under 7-8 years with myopic anisometropia and amblyopia who have demonstrated development of intolerance of contact lenses and full glasses correction. The functional category may include older children aged above 7-8 years with trained blunt-sightedness and a certain induced level of binocular vision, who do not tolerate full value glasses correction due to high anisometropia and cease to tolerate contact lenses. The main therapeutic aim of a refractive procedure in this category is to enable the preservation of the visual functions already gained, either without the necessity of optical correction or with tolerable full glasses correction following a reduction of anisometropia. The elective (facultative) indication area includes children and adolescents with a high refractive error that can be corrected by glasses, who do not tolerate contact lenses and do not wish to wear glasses (e.g. due to sport). It also includes children with a neurological disorder (e.g. DMO, autism) and higher bilateral ametropia, who resist wearing glasses and for whom application of contact lenses is extremely difficult or impossible. Only after a wealth of experience of refractive surgery in children (PRK, LASIK, LASEK, phakic intraocular lens) has been gained, on the basis of conducting a larger number of studies with a sufficient number of long-term observed paediatric patients in the area of the obligatory and functional categories, will it be possible to begin to apply methods of refractive surgery for facultative or elective types of indications.

This paper presents the result of a comparative study in which the methods used were LASEK and implantation of a pIOL in a group of children aged 3 to 7 years. It evaluates the effectiveness and safety of these two surgical procedures. Within the framework of this group, surgery was indicated following the repeated failure of conservative methods of correction – upon binocular intolerance of full glasses correction and intolerance of contact lenses. The functional results (visual acuity and quality of binocular vision) of this group of children are comparable with the results of a control group of children, in whom myopic anisometropia was corrected by contact lenses. To date no work has been published which would compare conventional therapy using contact lenses with refractive surgery (LASEK, implantation of pIOL) in children within this age category.

## COHORT AND METHODS

The groups of children who are the subject of our study were observed and treated for myopic anisometropia with

unilateral amblyopia from the age of 3 years. Group A consists of 43 children (43 eyes) in whom an external refractive photo ablation procedure was performed using an excimer laser (LASEK, 27 eyes) or implantation of a phakic intraocular lens into the anterior chamber (pIOL Verisyse 16 eyes) on one more myopic eye with amblyopia following the failure of conventional methods of correction.

In all the children in this group, blunt-sightedness was treated effectively by total occlusion of the dominant eye with full correction of ametropia. After an adjustment of the pleoptic regime to “reduced occlusion therapy” (50% of child's waking hours), problems occurred with binocular tolerance of full glasses correction, and a soft hydrogel contact lens was applied. Despite repeated training, some of the parents had problems with application of the contact lens, and other children, over periods of various length, progressively developed an intolerance to the lens (at least 3 types of soft contact lenses were tested, and the time for which the lens was tolerated in the eye progressively decreased to maximum 1-2 hours per day). Multizonal LASEK was performed on 27 children, and the remaining 16 underwent implantation of a phakic intraocular lens into the anterior chamber (pIOL Verisyse). In group B 37 children were treated conservatively using a contact lens or a combination of a contact lens (spherical error) and glasses lens (full correction of astigmatism above 1cyl D).

This group of eyes was a control group for comparison of the final results of visual acuity and quality of binocular vision. All the children in both groups were observed for a period of minimally 24 months. The preoperative and postoperative data in group A are analysed in the standard format usual for the presentation of results of refractive surgery from the perspective of effectiveness, safety, stability and predictability. All the parents signed a detailed informed consent to the operation. Both methods of refractive surgery in the stated specific indications were approved by the Ethical Commission of the Brno University Hospital, and implantation of pIOL was supported by the grant project IGA MZ ČR (NT12110-5/2011 NS 9284).

The age range of all the children in both groups was 3-7 years at the beginning of treatment. The mean age in group A was  $5.6 \pm 2.2$  years and in group B  $5.4 \pm 1.9$  years. The differences in the mean age, mean value of myopic anisometropia and mean best corrected visual acuity between both groups at the beginning of the study were not statistically significant. The preoperative data is presented in table 1.

Group A included children who did not tolerate binocular full glasses correction, and in whom contact lens intolerance progressively appeared, the value of myopic anisometropia was larger than 5.0 dioptres (D), with no other present ocular pathology and best corrective visual acuity of the dominant eye of 1.0. Optimum co-operation was requested from all the parents of the children in this study with regard to all aspects of treatment, in particular concerning adherence to the recommended regime of pleoptic therapy, which we consider to be of fundamental importance in order to attain a positive therapeutic effect.

The complex preoperative examination in group A inc-

cluded uncorrected and best corrected visual acuity (UVA and BCVA), examination of binocular vision (Worth, Randot, TNO stereotest), examination of aniseikonia (Aways New Aniseikonia Tests), manifest and cycloplegic refraction (autorefractometer Nidek ARK 800), biomicroscopy, computer topography (C scan-Technomed), pachymetry (Nidek UP 1000), tonometry (Goldmann applanation tonometry, Pro-Ton Tomey, Tono Pen), Schirmer test, measurement of axial length by ultrasound biometry (Nidek US 3000) and examination of the fundus by indirect ophthalmoscopy. Additionally, in all children before and after implantation of the pIOL, an analysis was performed of the anterior segment using Pentacam (Oculus) and endothelial microscopy (Nidek).

An orthoptic examination in all children demonstrated a parallel position of the eyes or horizontal deviation maximally up to 5 prismatic dioptres (PD) or a vertical deviation maximally up to 2 PD. All children were examined and checked at the orthoptic department of our clinic.

Visual acuity was examined on Snellen's optotypes, with the help of an E-test, H-test and on projection optotypes (Nidek). For the sake of statistical analysis the values of visual acuity are stated decimally. Quality of binocular vision was examined on a synoptophore, Worth test, stereopsis with the help of Randot and TNO-Stereotest (7, 8) and evaluated as presence of superposition, fusion of I to III and stereopsis.

#### LASEK method

All the operations on the children in group A were performed under general anaesthesia. The LASEK method used an excimer laser Nidek EC 5000. Before each procedure the surrounding area of the eye, eyelid and conjunctival sac was rinsed with 10% Betadine solution. Due to the impossibility of active co-operation of the patient and fixation under general anaesthesia, photo ablation was centred to the centre of the pupil.

Each procedure was planned as multizonal ablation with a final, widest 6.5 mm optical zone and 7.5 mm transitional zone. Correction of more than 8.0 D was performed in three optical zones of 5.0 mm, 5.5 mm and 6.5 mm. Before each

photo ablation and immediately afterwards, the cornea was rinsed with cooled BSS solution for a period of 30-40 seconds.

At the beginning of the laser subepithelial keratomileusis method, an imprint was created on the surface of the cornea of 8.0 mm (LASEK trephine-Janach J 2900) as the boundary of the epithelial incision within a scope of 270 degrees. The remaining 90 degrees within the meridian of 10 to 1 on the clock was left intact.

Subsequently a cone was attached with a diameter of 8.5 mm (LASEK alcohol solution cone-Janach J 2905), into which 20% ethyl alcohol solution in BSS was instilled and left on the surface of the epithelium for a period of 30 seconds, and then immediately microsurgically drained. After rinsing of the cornea with BSS solution an epithelial lobe was created (LASEK epithelial microhoe-Janach J2915A), which was rolled in a direction toward 12 o'clock. The surface of the cornea was rinsed with cooled BSS solution, dried, and the actual multizonal photo ablation was performed. There followed very careful repositioning of the epithelial fold precisely to the boundaries of the intact epithelium (LASEK blunt spatula-Janach, J 2920A) and application of a therapeutic hydrogel contact lens (Acuvue, Vistakon, 9.1 mm). Instillation of tobramycin and diclofenac at the end of each procedure. The contact lens was left in situ for a period of 2-4 days and all the children were checked during hospitalisation. In the first week Tobrex gtt drops were applied 6x daily, Naclorf gtt 5x daily. From the beginning of the second postoperative week local corticotherapy was commenced with 0.1% fluorometholon (Flucon or Efflumidex gtt) 5x daily, which continued in a reducing dose for a period of 6 months.

#### Implantation method of pIOL

Implantation of the phakic intraocular lens Verisyse (AMO) into the anterior chamber was performed according to the standard operating protocol of the AMO company. The depth of the anterior chamber was above 3 mm in all eyes. Following peritomy of the conjunctiva and Tenon's capsule, a scleral tunnel incision was prepared with a width of

**Table 1** Preoperative data on both groups of children at the beginning of treatment

	Group A (LASEK, pIOL)	Group B (contact lenses)
Total number of children / eyes	43/43	37/37
Average age $\pm$ SD (range, years)	5.6 $\pm$ 2.2 (3 to 7)	5.4 $\pm$ 1.9 (3 to 7)
Average observation period $\pm$ SD (range, years)	3,4 $\pm$ 2,9 (2 až 8) -9,45 $\pm$ 2,47 (-6,0 až -18,25)	4,1 $\pm$ 2,7 (2 až 9) -8,95 $\pm$ 2,82 (-5,75 až -17,5)
Average SE $\pm$ SD (range, D)*	3.4 $\pm$ 2.9 (2 to 8) -1,45 $\pm$ 1,31 (-0,25 až -2,5)	-8,41 $\pm$ 1,85 (-5,0 až -14,75) -1,62 $\pm$ 1,34 (-0,5 až -3,5)
-9.45 $\pm$ 2.47 (-6.0 to -18.25)	4.1 $\pm$ 2.7 (2 to 9)	0,23 $\pm$ 0,19
	0%	0%

LASEK = laser subepithelial keratomileusis, pIOL = phakic intraocular lens, SE = spherical equivalent of refraction, SD = standard deviation, BCVA = best corrected visual acuity expressed decimally, \* = mean value of SE of cycloplegic refraction of more myopic eye with amblyopia, # = mean difference in spherical equivalent of cycloplegic refraction

6 mm in the meridian of 11 and 1 o'clock. Peripheral pericentesis of the cornea in the meridian of 10 and 2 o'clock.

Miostat and Viscoat (Alcon) were applied to the anterior chamber. Afterwards the scleral tunnel incision was completed and basal iridectomy at 12 o'clock was always performed perioperatively according to the recommendation of AMO in order to reduce the risk of pupillary block. Implantation of the pIOL with enclaving of both haptic parts of the lens in the peripheral tissue of the iris in the meridian of 3 and 9 o'clock. During enclaving, a precise part of the stroma of the iris is fixed into specific small clips on both ends of the haptic part of the pIOL. After removal of the viscoelastic material, suturing of the sclera and conjunctiva is performed. The peripheral pericentesis are closed by hydration of the corneal wound. After surgery Tobradex gtt and Indocollire gtt are applied 5x daily for a period of 1 week, then Flarex gtt daily for a period of 2 weeks. All the children were checked daily in the first week after surgery, then after 1, 3, 6, 9, 12, 18 and 24 months and subsequently at least once every six months. At these follow-up examinations, visual acuity (UVA, BCVA) was examined, as well as manifest and cycloplegic refraction, keratometry, pachymetry, topography, biomicroscopy, examination of the fundus, biometry, (always after 6 months), tonometry, endothelial microscopy, orthoptic status and examination of the state of binocular vision. After surgery all the children continued in treatment of amblyopia by reduced occlusion of the dominant eye (50% of waking hours) supplemented with active pleoptic training at our department.

All the children in group B with correction by contact lenses were checked at three-monthly intervals throughout the entire observation period. The checks in this group included examination of visual acuity, orthoptic status and binocular function, manifest and cycloplegic refraction, keratometry and biomicroscopy. On the basis of the examined refraction, current full correction of refractive error was applied according to requirement by contact lenses, and in the case of astigmatism supplemented by glasses correction. The regime of pleoptic therapy was identical in both groups of children. A Student T-test, Mann-Whitney test and Fisher's exact test were used for the statistical analysis. Value of  $P < 0.05$  were interpreted as statistically significant.

## RESULTS

In group A the preoperative mean spherical equivalent (SE) of refraction in the more myopic eye of  $-9.45 \pm 2.47$  D (range:  $-6.0$  to  $-18.25$  D) was reduced to the value of  $-1.48 \pm 1.13$  D (range:  $+0.75$  to  $-2.25$  D) 2 years after surgery. A comparison of the mean refraction (SE) of the operated and other eye is presented in graph 1.

Mean SE of refraction in the non-operated eye was improved after 2 years of observation from the value of  $-0.57 \pm 1.18$  D to  $-1.79 \pm 1.04$  D.

The preoperative value of the difference in SE between both eyes of  $-8.78 \pm 2.19$  D was reduced 2 years after surgery to  $-0.35 \pm 0.27$  D. A 96% reduction of anisometropia was

thus achieved.

Graph 2 presents a comparison of intended and attained surgical correction of refractive error in the spherical equivalent 2 years after surgery, when 83% of eyes were within an interval of  $\pm 1.00$  D.

The improvement of best corrected visual acuity (BCVA) expressed by the number of gained rows on Snellen's optotypes 2 years after surgery in group A, as well as the improvement in BCVA 2 years after treatment using partial occlusion of the dominant eye and contact lens correction on the more myopic amblyopic eye in group B is documented in graph 3 and table 2.

In group A 12% of eyes had BCVA without change, 28% improved within the range of 1-3 rows and 61% of eyes had improved vision within the range of 4 to 8 rows in comparison with the preoperative level of BCVA. In group B corrected vision remained unchanged in 27% of eyes, 51% of eyes improved within the range of 1-3 rows and 22% improved within the range of 4 to 8 rows.

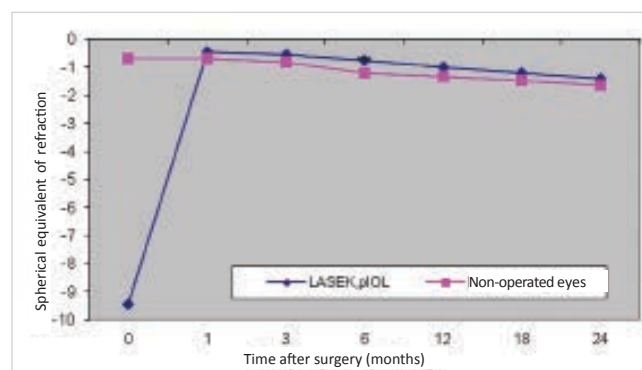
The difference in the number of eyes in which visual acuity improved within the range of 4 to 8 rows on Snellen's optotypes was statistically significant in favour of the group of children with permanent correction of anisometropia with the help of refractive surgery ( $P = 0.0326$ ). Deterioration of visual acuity did not occur in any of the children in the entire studied cohort.

The mean preoperative decimal corrected visual acuity in group A was  $0.28 \pm 0.22$ , which improved to  $0.78 \pm 0.19$  2 years after surgery and pleoptic therapy.

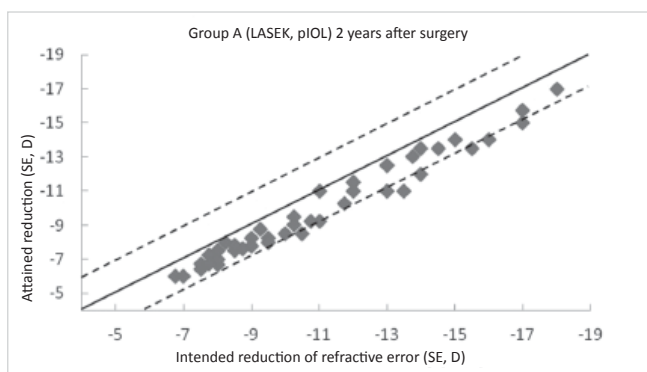In group B the mean corrected visual acuity at the beginning of treatment was  $0.23 \pm 0.19$ , improving to  $0.42 \pm 0.15$  after 2 years of treatment of amblyopia with contact lens correction.

The difference in the mean final corrected visual acuity between both groups was statistically significant ( $P = 0.0215$ ).

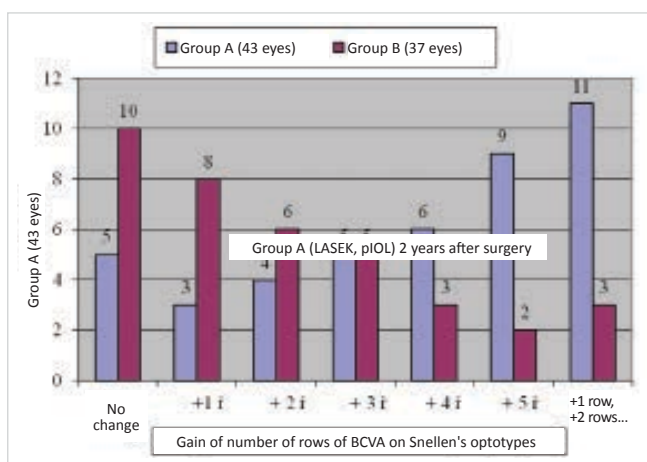
Examination of binocular vision with full correction (contact lens, if applicable in combination with glasses) at the beginning of the study in group A demonstrated superposition in 19% of children and fusion I in 8% of children. In group B, 15% of the children receiving conservative therapy had superposition and 9% had fusion I. At the beginning of treatment stereopsis was not present in any case. After 2



**Graph 1** Mean spherical equivalent of refraction in operated and non-operated eyes in group A over observation period



**Graph 2** Comparison of intended and attained correction of refractive error expressed in spherical equivalent 2 years af-



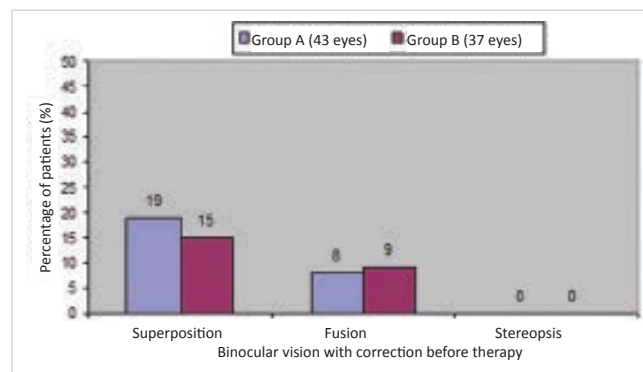
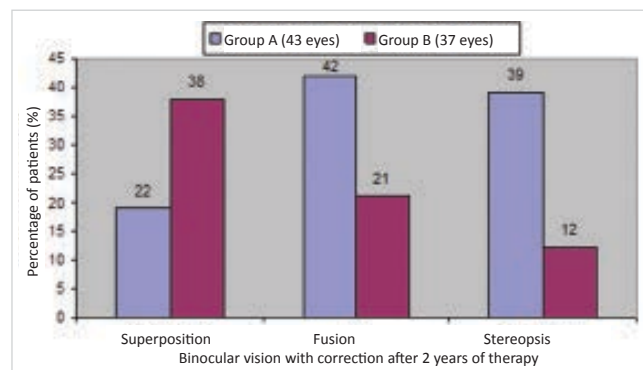
**Graph 3** Comparison of best corrected visual acuity before therapy and 2 years later in both groups

years of treatment of amblyopia in a reduced half-day occlusion regime and correction of the more myopic eye with a contact lens or laser photo ablation, quality of binocular vision improved in both groups (graph 4). However, a higher percentage of children in group A with permanent laser correction gained fusion or stereopsis (in total 81% of children) in comparison with group B (fusion or stereopsis in a total of 33% of children). This difference in the quality of gained binocular vision after 2 years of therapy between both groups (table 3) was statistically significant ( $P = 0.0414$ ).

Upon an evaluation of complications following LASEK surgery we did not record any early or later postoperative complications in our young patients. The mean time of healing of the epithelium following LASEK surgery was  $2.26 \pm 0.59$  days (range: 2 to 4 days). After this time the corneal epithelium was biomicroscopically intact with a negative fluorescence

test. The course of healing in the first days after surgery was calm and pain free in all children. In certain cases we recorded only mild discomfort, with irritation of the eye and lachrymation. After implantation of a pIOL Verisyse there were not perioperative or postoperative complications. The change in the number of endothelial cells from the mean value of 2913/mm<sup>2</sup> preoperatively to 2839/mm<sup>2</sup> 2 years after surgery was not statistically significant ( $P = 0.7645$ ). In two children it was necessary to perform repositioning and repeat fixation of one haptic of the pIOL more than 2 years after surgery due to post-traumatic luxation of the pIOL following severe contusion of the bulb. Visual acuity after repositioning and centration of the pIOL returned to the original value as before the injury. No severe complications were recorded in direct connection with surgery and general anaesthesia. Transitory ovalisation of the pupil corrected itself spontaneously in 5 eyes and disappeared within 3-4 weeks of the operation. Incidence of secondary glaucoma was not recorded in any case.

Fig. 1 a) illustrates repositioning of the epithelial fold after the performance of photo ablation and fig. 1 B) shows the line – boundary between the repositioning and intact



**Graph 4** Binocular vision with optimum correction before therapy and 2 years later in both groups of children

**Table 2** Change of corrected vision on Snellen's optotypes after 2 years of therapy in both groups

Group	No change	+1 row	+2 rows	+3 rows	+4 rows	+5 rows	+6 rows or more
A (43 eyes)	5 (11.6%)	3 (7.0%)	4 (9.3%)	5 (11.6%)	6 (14.0%)	9 (21.0%)	11 (25.6%)
B (37 eyes)	10 (27%)	8 (21.6%)	6 (16.2%)	5 (13.5%)	3 (8.1%)	2 (5.4%)	3 (8.1%)
	$P < 0.05$	$P < 0.05$	$P < 0.05$	$P < 0.05$	$P < 0.05$	$P < 0.05$	$P < 0.05$

**Table 3** Quality of binocular vision 2 years after therapy in both groups of children

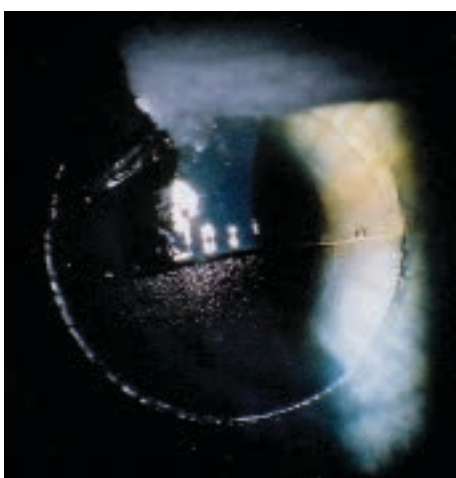
Group	Binocular vision, % of children		
	Superposition	Fusion	Stereopsis
A (n = 43)	22%	42%	39%
B (n = 37)	38%	21%	12%

epithelium following adaptation of the epithelial fold to the original stromal bed using the LASEK method.

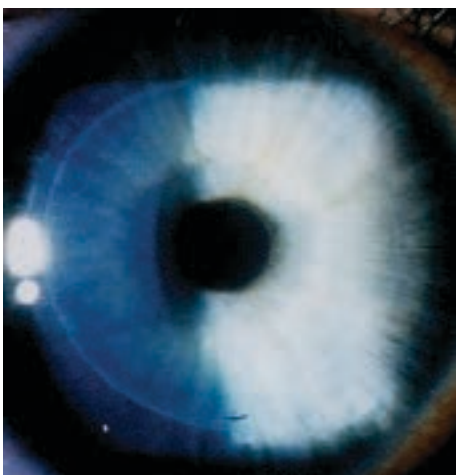
Fig. 2 shows an implanted phakic intraocular lens (AC pIOL) Verisyse in an eight year old child.

### DISCUSSION AND CONCLUSIONS

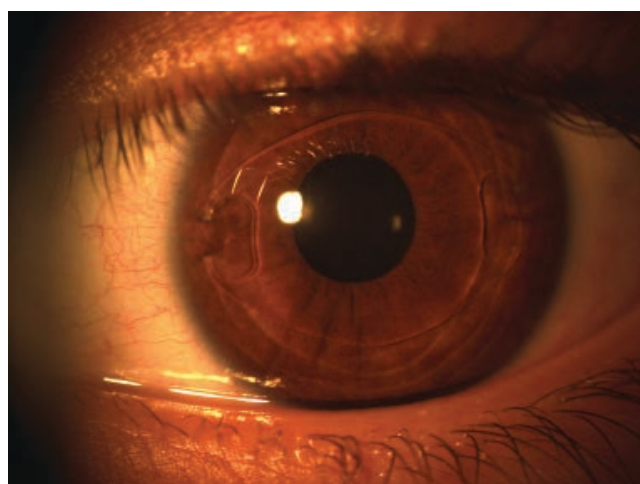
Refractive surgery is not commonly applied in the child population. Conservative therapy involving correction with contact lenses or their combination with glasses, with adequate pleoptic training during early childhood age re-



**Fig. 1 a)** Repositioning of epithelial fold after performance of photo ablation



**Fig. 1b)** Line – boundary between repositioning and intact epithelium after adaptation of epithelial fold into original stromal bed using LASEK method



**Fig. 2** Implanted phakic intraocular lens (AC-pIOL) Verisyse in eight year old child

mains an effective therapeutic modality upon high myopic anisometropia with amblyopia in the majority of these children. However, some of these patients may be potential candidates for refractive surgery.

The main aim of our clinical trial was to reduce the refractive error in the more myopic eye with amblyopia at an age in which blunt-sightedness can still be influenced by therapy, similarly to the development and reinforcement of binocular functions. We presupposed binocular tolerance of full glasses correction following a significant reduction of anisometropia, which was a fundamental condition for the development of binocular vision. Our group of children with refractive external laser photo ablation can be included in the “obligatory” category of indications according to Davidorf (13). Intolerance of contact lenses was demonstrated in these children following repeated testing of at least 3 types of soft contact lenses. The final results of visual functions after surgery, pleoptic therapy and training of binocular vision were compared with a control group of children with correction of myopic anisometropia by contact lenses and the same regime of pleoptic therapy.

Jeffrey et al. (19) compared the long-term effect of intensive total occlusion with partial reduced occlusion of the dominant eye on resulting visual acuity and quality of attained binocular vision in children following surgery for a unilateral congenital cataract. The first group of children had intensive occlusion (80-100% of waking hours) and the second group had reduced occlusion for a time of 25-50% of waking hours. The results of this prospective study demonstrated statistically significantly better resulting quality of binocular vision in the group of children with the reduced occlusion regime. The application of reduced occlusion prevailed also in our study.

The success of treatment of amblyopia in anisometropia is influenced by several factors. The greater the anisometropia, the more severe the amblyopia in general. The results of pleoptic therapy are better when it is commenced at the earliest possible age. Another significant factor for a good prognosis of amblyopia treatment is optimum co-operati-

on of the parents. If parents do not respect all the rules of pleoptic therapy precisely, it is not possible to expect any significant effect even under the conditions of adequate correction of ametropia. In our study the co-operation of the children and their parents with the professional treatment staff was without problems.

Refractive surgery with an excimer laser (PRK and LASIK methods) for a significant reduction of myopia in the child population has demonstrated its safety and efficacy in a range of published studies (1, 2, 4, 5, 9, 24, 25, 28). The previous studies of both methods used on children do not state any more serious complications. The professional literature describes the potential advantages of the LASIK method as against PRK (14, 18, 20, 21, 26, 30), as well as the potentially very serious perioperative and postoperative complications in connection with the creation of a lamella by the microkeratome and with the process of healing of the lamella in the LASIK method (10, 16, 17, 23, 27, 29, 32).

We began using the PRK method on children at our clinic in 1995 due to its lesser invasiveness. However, from 2002 we gradually began to use the method of laser subepithelial keratomileusis (LASEK) on children on the basis of our own very positive experiences and results in the correction of myopia in our adult patients (6). The LASEK method suitably combines the advantages and eliminates the disadvantages of the PRK and LASIK methods. In the case of perioperative problems with the creation and repositioning of the epithelial fold using the LASEK method, it is possible to convert and complete the procedure as PRK.

In the international professional literature it is possible to find a number of studies relating to refractive laser surgery in children aged less than 7 years, in which treatment of amblyopia may be sufficiently effective.

Alio et al. (2) treated 6 children with myopic anisometropia and amblyopia aged 5 to 7 years using the PRK method. The mean spherical equivalent of the refractive error was reduced after surgery by 77.9% of the initial preoperative value. They observed more significant regression of myopia in 2 children within 1 year. The authors describe the development of a more severe degree of haze, which however gradually disappeared within 1 year of surgery. Preoperative BCVA was improved after surgery in all the patients.

Agarwal et al. (1) used the LASIK method on 16 children aged 5 to 11 years (average 8.4 years). The mean preoperative spherical equivalent of -14.88 D was reduced to -1.44 D one year after surgery. One patient had a loss of 1 row of BCVA, two gained 1 row and the others had a preserved level of preoperative BCVA. In three eyes 2nd degree haze remains in the area of healing of the corneal lamella.

Astle et al. (3) performed PRK in 40 eyes of 27 children aged 1 to 6 years due to myopic anisometropia and amblyopia (15 eyes), bilateral high myopia (20 eyes) also high myopia after keratoplasty (3 eyes), and in two cases superficial scars simultaneously with anisometropia and amblyopia. All the operations were performed under general anaesthesia.

The mean preoperative refraction (SE) of -10.86 was reduced to -1.37 D 1 year after surgery. Mean visual acuity (BCVA) improved from 20/70 to 20/40. 40% of eyes were

at an interval of  $\pm 1.0$  D from the desired refraction. Three eyes had 3rd degree haze following surgery, in one case the intensity reduced spontaneously to 2nd degree, and in two eyes a significant reduction of haze was attained following PRK re-operation. The study in question incorporated children within an age range in which treatment of amblyopia can be highly effective. The authors demonstrated the efficacy and safety of PRK in their group of children for correcting bilateral high myopia and treating myopic anisometropia and amblyopia.

In comparison with the results of the above study (3), in our group of children operated on by the LASEK method and implantation of a pIOL, the mean decimal best corrected visual acuity (BCVA) improved from the value of 0.23 to 0.78 2 years after surgery at an interval of  $\pm 1.00$  D from the desired refraction. Despite the fact that correction of high myopia was performed in our group of children, no deterioration of BCVA was found in any patient in comparison with preoperative vision. Twelve percent of eyes had no change of BCVA after surgery, 27.9% of eyes gained 1 to 3 rows and 60.5% of eyes had an improvement of BCVA within the range of 4 to 8 rows on Snellen's optotypes 2 years after surgery and treatment of amblyopia. In the control group of 37 children treated with contact lenses, if applicable in combination with glasses, with the same method of pleoptic therapy, there was also an improvement of visual acuity (BCVA), but to a lesser extent than in the group of children with laser correction and implantation of a pIOL. After 2 years of amblyopia treatment, in this group 21.6% of eyes showed improvement of visual acuity within the range of 4 to 8 rows on Snellen's optotypes. It is also of interest to compare the quality of attained binocular vision in both groups of children in our study. Eighty one percent of children in the group of refractive surgery as against 33% of children in the group using contact lens correction had binocular vision of quality fusion or stereopsis after 2 years of treatment. At the beginning of our study the differences in the initial mean refraction and the size of amblyopia between both groups were not statistically significant. All the patients had the same type of amblyopia treatment and training of binocular vision. It is probable that the better functional results in children following a refractive procedure were caused by permanent correction of the refractive error with a significant reduction of anisometropia with the help of a LASEK operation and implantation of a pIOL.

In conclusion it is possible to state that both methods, LASEK external laser photo ablation and implantation of a phakic intraocular lens into the anterior chamber (AC pIOL) represent an effective and safe therapeutic alternative upon correction of high myopic anisometropia and in the treatment of connected amblyopia in children aged 4 to 8 years who cease to tolerate contact lenses. Visual acuity with correction and quality of binocular vision were significantly better in the children with permanent correction of anisometropia using refractive surgery than in the children treated conservatively using contact lenses. An important

condition for attaining a successful therapeutic effect is good co-operation of the parents during long-term amblyopia training.

We hope that the results of the clinical trials taking pla-

ce also in foreign centres will contribute to confirming the efficacy and safety of refractive surgery prudently indicated upon intolerance of contact lenses even in this low age category of the child population.

## LITERATURE

1. **Agarwal A., Agrawal A., Agarwal T., Siraj A.A., et al.:** Results of pediatric laser in situ keratomileusis. *J. Cataract Refract Surg*, 2000; 26, 684–689.
2. **Alio J.L., Artol A., Claramonte P., Ayala M.J., Chipont E.:** Photorefractive keratectomy for pediatric myopic anisometropia. *J. Cataract Refract Surg*, 1998; 24, 327–330.
3. **Astle W. F, Huang P.T., Ells A.L., et al.:** Photorefractive keratectomy in children. *J. Cataract Refract Surg*, 2002; 28, 932–941.
4. **Autrata R., Řehůřek J.:** Clinical results of excimer laser photorefractive keratectomy for high myopic anisometropia in children: Four-year follow-up. *J. Cataract Refract Surg*, 2003, 29, 4, p. 694–702. ISSN 0886-3350
5. **Autrata R., Řehůřek J.:** LASEK and PRK versus Conventional Treatment of Myopic Anisometropic Amblyopia in Children : A prospective comparative study. *European and Am J Cataract Refract Surg*, 2004, 30, 1: 74–84. ISSN 0886-3350.
6. **Autrata R., Řehůřek J.:** Laser-assisted subepithelial keratomileusis for myopia: Two-year follow-up. *J. Cataract Refract Surg*, 2003, 29, 4, p. 661–668. ISSN 0886-3350.
7. **Birch E., Williams C., Hunter J., Lapa M.C., ALSPAC “Children in Focus” study team:** Random dot stereoacuity of preschool children. *J. Pediatr. Ophthalmol. Strabismus* 1997; 34, 217–22.
8. **Birch E.E., Salomao S.R.:** Infant random dot stereoacuity cards. *J. Pediatr Ophthalmol Strab*, 1998; 35, 86–90.
9. **Bluestein E.L.:** PRK useful in some young patients with amblyopia – US study suggests. *Eurotimes*, 2001; 6, 28.
10. **Castillo A., Diaz-Valle D., Gutierrez A.R., et al.:** Peripheral melt of flap after laser in situ keratomileusis. *J. Refract Surg*, 1998; 14, 61–63.
11. **Claringbold T.V.:** Laser-assisted subepithelial keratectomy for the correction of myopia. *J. Cataract Refract Surg*. 2002; 28, 17–22.
12. **Collins J.W., Carney L.G.:** Visual performance in high myopia. *Curr Eye Res*, 1990, 9, 217–223.
13. **Davidorf J.M.:** Pediatric refractive surgery. *J. Cataract Refract Surg*, 2000; 26, 1567–1568.
14. **El Maghraby A.:** Prospective randomized bilateral comparison of laser-assisted in-situ keratomileusis and photorefractive keratectomy for myopia. *Ophthalmology* 1995; 102(suppl): 99.
15. **Epstein D., Fagerholm P., Hamberg-Nystrom H., Tengroth B.:** Twenty-four month follow-up of excimer laser photorefractive keratectomy for myopia. *Ophthalmology*, 1994; 101, 1558–1564.
16. **Geggel H.S., Talley A.R.:** Delayed onset keratectasia following laser in situ keratomileusis. *J. Cataract Refract Surg*, 1999; 25, 582–586.
17. **Gimbel H.V., Andreson Penno E.E., van Westenbrugge J.A., et al.:** Incidence and management of intraoperative and early postoperative complications in 1000 consecutive laser in situ keratomileusis cases. *Ophthalmology*, 1998; 105, 1839–1847.
18. **Guell J., Muller A.:** Laser in situ keratomileusis (LASIK) for myopia from –7 to –18 diopters. *J. Refract Surg*, 1996; 12, 222–228.
19. **Jeffrey B.G., Birch E.E., Stager D.R. Jr, Stager D.R. Sr, et al.:** Early binocular visual experience may improve binocular sensory outcomes in children after surgery for congenital unilateral cataract. *J AAPOS*, 2001; 5, 209–216.
20. **Knorz M.C., Liermann A., Wiesinger B., et al.:** Correction of myopia using laser in situ keratomileusis. *Klinische Monatsblätter Fur Augenheilkunde*, 1996; 208, 438–445.
21. **Kremer F., Dufek M.:** Excimer laser in situ keratomileusis. *J Refract Surg*, 1995; 11, 244–247.
22. **Lee J.B., Seong J.G., Lee J.H., et al.:** Comparison of laser epithelial keratomileusis and photorefractive keratectomy for low to moderate myopia. *J. Cataract Refract. Surg*. 2001; 27, s. 565–570.
23. **Melki S.A., Talamo J.H., Demetriades A-M.:** Late traumatic dislocation of laser in situ keratomileusis corneal flaps. *Ophthalmology*, 2000; 107, 2136–2139.
24. **Nano H.D. Jr, Muzzin S., Irigaray F.:** Excimer laser photorefractive keratectomy in pediatric patients. *J. Cataract Refract Surg*, 1997; 23, 736–739.
25. **Nucci P., Drack A.V.:** Refractive surgery for unilateral high myopia in children. *J AAPOS*, 2001, 5, 348–351.
26. **Pallikaris I.G., Siganos D.S.:** Excimer laser in situ keratomileusis and photorefractive keratectomy for correction of high myopia. *J Refract Corneal Surg*, 1994; 10, 498–510.
27. **Quiros P.A., Chuck R.S., Smith R.E., et al.:** Infectious ulcerative keratitis after laser in situ keratomileusis. *Arch Ophthalmol*, 1999; 117, 1423–1427.
28. **Rashad K.M.:** Laser in situ keratomileusis for myopic anisometropia in children. *J Refract Surg*, 1999; 15, s. 429–435.
29. **Smith R.J., Maloney R.K.:** Diffuse lamellar keratitis; a new syndrome in lamellar refractive surgery. *Ophthalmology*, 1998; 105, 1721–1726.
30. **Stodulka P.:** LASIK = laser in situ keratomileusis. Initial experience. *Čs Oftal*, 1996; 52, 73–81.
31. **Townshend A.M., Holmes J.M., Evans L.S.:** Depth of anisometropic amblyopia and difference in refraction. *Am J Ophthalmol*, 1993, 116, 431–436.
32. **Walker M.B., Wilson S.E.:** Incidence and prevention of epithelial growth within the interface after laser in situ keratomileusis. *Cornea*, 2000; 19, 170–173.