

# OPTICAL CHARACTERISTICS OF MYOPIC CORRECTION BY ORTHOKERATOLOGICAL CONTACT LENSES (CASE STUDY)

## SUMMARY

**Introduction:** Orthokeratology lenses present a special type of hard contact lenses, which is used especially for myopic correction. The lenses are applied during the night, when thanks to their special shape cause temporally (reversible) change of the cornea shape. During the day, there is not necessary to wear any other refractive correction. Due to the wearing regimen, there is, comparing to the classical contact lenses, higher risk of health complications. For their safe use, it is necessary to pay attention to the application of lenses of adequate parameters, follow up the care and hygiene precautions, regular controls and early treatment of possible problems. The application of contact lenses should be done by experienced and well-educated expert in contact lens fitting. In the Czech Republic, this method is practically not used.

**Aim:** The aim of the case report was to follow up the course of concrete application of orthokeratology lenses for myopic correction from the optic (refractive) point of view, and to evaluate the optic changes in the system of the eye.

In the followed up subject, there were measured subjective changes in refraction, visual acuity, corneal curvature, corneal and whole eye aberrations, and corneal thickness during the period of one month after the beginning of lens application (initial phase). The same parameters were followed-up during one-month period since the termination of lens wearing for three months (second phase). The subject was a woman, 24 years old, myopic, with the refractive error in the right eye  $-3.0$  spherical diopters and astigmatism of  $-0.25$  cylinder in the axis  $90^\circ$ , and in the left eye  $-2.75$  spherical diopters without astigmatism; without ophthalmologic or systemic diseases. The full correction of the refractive error after the orthokeratology lenses application occurred approximately after four nights (wearing the lenses overnight). Concurrently, during the day, slight recurrence to original values was evident. With the decreased refractive error, the uncorrected visual acuity improved accordingly. Further, the flattening of the central cornea was observed, e.g. increasing of the central cornea curvature diameter (maximum change was  $0.22$  mm in the right and  $0.28$  mm in the left eye) and slight thinning. The adverse accompanying optic phenomenon was increasing of the aberrations of higher orders, which presented subjectively by decreased visual acuity under mesopic conditions. One month after the termination of contact lenses wearing, all the followed-up parameters returned to original values.

**Key words:** orthokeratology, orthokeratology contact lenses, myopic correction, hard contact lenses, rigid gas-permeable (RGP) lenses

*Čes. a slov. Oftal., 73, 2017, No. 1, p. 17–23*

## INTRODUCTION

Orthokeratology is a technique for correcting refractive errors, in particular myopia, which uses specially designed hard contact lenses for temporary (fully reversible) change of the shape of the cornea [9, 17, 27]. The foundations of the method were laid more than half a century ago by George Jessen, and since that time it has been continually improving [9, 17, 27]. Orthokeratological lenses are usually used at night. During sleep they shape the cornea in such a manner that after removal sharp vision is possible without further correction. Worldwide this method is relatively widespread, and recently has been the subject of substantial discussion and investigation, especially in connection with the possibility of retarding the advance of myopia in children and adolescents [12, 22, 26]. In the Czech Republic orthokeratological lenses are not used at present in regular practice.

Orthokeratological lenses have “reverse geometry”, which enables the creation of a specific profile of the lachrymal

film beneath the lens. This generates forces which act upon the cornea and influence its shape, thickness and therefore also its refractivity [9, 17, 27]. The largest changes occur in the epithelial layer, which is thinned in the central part and thickened in the central periphery upon correction of myopia. The mechanism of changes on the cornea has not yet been precisely clarified. Most probably a number of factors play a role in this mechanism, in particular compression of the epithelial cells in the central part of the cornea [10], redistribution (migration) of epithelial cells [10, 28, 31] and curvature of the cornea [19]. However, some more recent studies (e.g. [32]) refute the last of these factors.

Nevertheless, from the perspective of healthcare this method brings with it risks, primarily in connection with wearing orthokeratological lenses during the night. For example, this increases the risk of incidence of microbial keratitis, similarly as with other types of contact lenses worn overnight [14, 27]. Basal secretion of tears is also reduced, and the overall stability of the lachrymal film is influenced [14]. It is also po-

Mýlková M., Pluháček F.

Department of Optics, Faculty of Science,  
Palacký University Olomouc,  
Head of the Department: Doc. Mgr.  
Jaromír Fiurášek, Ph.D

*The authors of the study declare that no conflict of interest exists in the compilation, theme and subsequent publication of this professional communication, and that it is not supported by any pharmaceuticals company.*



Mgr. Magdaléna Mýlková  
EOK Lexum  
Masná 3a  
702 00 Ostrava 1  
e-mail: mylkova@lexum.cz

ossible to observe colouring of the cornea in connection with the possible adhesion of the lens to the eye during the night [9, 14, 17]. Upon long-term wearing, ring-shaped ferrous deposits may appear in the subepithelial layer, as well as other defects, which nevertheless have no influence on vision and disappear after discontinuation of wearing the lenses [9, 14]. Changes also occur in the biomechanics of the cornea, such as a reduction of corneal hysteresis [14]. These changes also are stated as reversible. With regard to the reported adverse accompanying phenomena, it is necessary to place increased emphasis on the correct application of the lenses, on strict adherence to the procedures for care of lenses, on hygiene and thorough attendance of regular check-ups, and timely resolution of any problems which may occur [14].

The case study presented here aimed to observe the course of application of orthokeratological lenses for myopia correction from a purely optical perspective, and describe in detail the changes in the optical system that occur in the different phases of orthokeratological correction. Specifically, changes were observed at the beginning of correction and subsequently following discontinuation of wearing the lenses.

## METHODOLOGY

The case study included one normal healthy subject (woman, aged 24 years) without ocular pathologies or anomalies, who had not undergone any surgical procedure. Both eyes were observed, the basic initial parameters of which are summarised in table 1. Specifically the course of the values of subjective refraction were measured, as well as vision without applied correction, radius of corneal curvature,

central corneal thickness and higher-order corneal optical aberrations (table 1).

Orthokeratological lenses sleep&see made by the Technolens company were used in the study. The lenses were designed and their suitability verified by an experienced applicator (A. Holschbach, Hochschule Aalen, Germany). Our own data gathering took place in the optometric laboratory of Palacký University in Olomouc. The specific parameters of the used lenses are summarised in table 2. The target correction for the right eye was -3.30 D, for the left eye -2.70 D (table 2).

The first phase of the study observed changes at the beginning of the process of orthokeratological correction. Measurement of the observed parameters was conducted on the 1st, 2nd, 3rd, 4th, 5th, 8th, 9th, 36th and 37th day after the first sleep with the lenses. All the measurements were conducted at the same time of the day, always 1 hour after removal of the lenses (specifically always at 8:00 am) and in the evening (at 20:00, i.e. 13 hours after removal of the lenses). The subject slept 7 hours every night wearing orthokeratological lenses. Afterwards correction in the same regime was applied without measurement over a total period of 3 months from the first sleep. Subsequently the values were measured on the 1st, 2nd, 3rd, 4th, 7th, 8th, 9th, 10th, 14th, 17th, 24th and 31st day after discontinuation of wearing the lenses. Measurement was conducted in the morning hours and was concluded on the 31st day, when the observed parameters approximated the original values.

Vision V was measured by the interpolation method, with the aid of an LCD optotype with a logarithmically ordered set of British letters characters at an examining distance of 6 m,

Table 1: Eye parameters before contact lens wearing. Abbreviations sph and cyl represent spherical and cylindrical part of the refractive correction, ax is the axis of the cylinder. RH a RV represents horizontal and vertical corneal curvature.

Parametr	Right eye	Left eye
Refraction	sph -3,00 D cyl -0,25 D ax 90°	sph -2,75 D
Best corrected visual acuity	1,58	1,58
Uncorrected visual acuity	0,1	0,12
R <sub>H</sub> [mm]	7,91	7,93
R <sub>V</sub> [mm]	7,80	7,81
Corneal thickness [µm]	531	520

Table 2: Parameters of contact lenses used in the study.

Parameter	Right eye	Left eye
Central curvature [mm]	8,73	8,65
Peripheral curvature [mm]/eccentricity in 30°	7,90/0,70	7,95/0,65
Lens power in the air [D]	+0,75	+0,75
Lens diameter [mm]	11,00	11,00
Back optic zone diameter [mm]	6,00	6,25
Deviation of lens sag of orthokeratology lens from the lens sag of aspheric lens with the same parameters [µm]	0	0
Central lens thickness [mm]	0,22	0,22
Lens material	Boston XO Vert	Boston XO Violet

and subsequently converted into final decimal form. Refraction was determined subjectively with the use of a testing set and testing frame. At the same time subjective evaluation of vision was briefly recorded. The radius of corneal curvature, corneal topography and corneal aberrations were measured on a Keratograph 3 instrument produced by the Oculus company, corneal thickness was determined by a Pachycam (Oculus) optical pachymeter. Specifically 3rd and 4th order aberrations were observed according to the "Zernike classification" [29, 30], and always uniformly converted for the referential ring area of the cornea with a diameter of 5 mm. The size of the aberrations was represented by the parameter RMS (root mean square), which represents the average standard deviation of the wavefront caused by the observed aberration or group of aberrations from the ideal shape of the wavefront [29, 30]. The deviation of RMS was determined summarily for the group of 3rd and 4th order aberrations (RMS3,4). The stated parameters can be calculated from the "Zernike coefficient" of individual aberrations (see [29, 30]).

## RESULTS

The course of the observed parameters in both phases of the study, i.e. at the beginning of correction and after the end of correction, is graphically illustrated in fig. 1-3 and 5. The topographical changes of the cornea are indicated on sagittal topographical maps including a differential map in fig. 4.

### Changes of subjective refraction and vision

With regard to the fact that the values of the cylindrical part of correction and their changes were low throughout the entire course of the observation period (within the range of 0 to -0.5 D), and were of a random character (including orientation of the axis), in the case of subjective refraction only spherical equivalent SE was evaluated. From the graphs in fig. 1 and 2 it ensues that changes of vision V correspond with changes of SE. The largest corrective effect took place after the first night with the lenses, when the largest change occurred (by 1.38 D in the

right eye and by 1.25 D in the left eye). Full correction of the refractive error took place after the fourth to fifth night, when the maximum vision was also achieved and subsequently remained virtually unchanged. Smaller changes of refraction (slight hypermetropisation) took place up to the 9th day (Fig. 1). After discontinuation of wearing the lenses the refractive error gradually returned, in which the largest change was observed during the first two days, by 2.25 D in the right eye and by 1.88 D in the left eye. The subsequent return was slower, the original values were reached approximately after 14 days. In accordance with the increase in the error, uncorrected vision perceptibly deteriorated up to approximately the 3rd day, when it reached values of 0.14 for both eyes, and subsequently changed only imperceptibly (Fig. 2).

### Subjective perception of vision

Vision was evaluated subjectively by the patient as sufficiently sharp on the morning of the third day after the first application of the lenses, but a slight deterioration was reported toward the evening. From the fifth day vision was subjectively acceptable all day under normal lighting conditions. However, vision in twilight was disturbed by the perception of halo effects and slight monocular double vision, more perceptibly in the right eye. These effects, together with glare, hampered motor vehicle driving in the evening and at night. Reading in the evening was also possible only with good lighting (in twilight the eyes tired very rapidly). Vision during the day (especially outside) was evaluated as perfect. After discontinuation of wearing lenses, the original correction by eyeglasses again became comfortable for all day wearing on around the tenth day. Vision in twilight improved within two days after discontinuation of wearing the lenses.

### Metric parameters of cornea

During the course of the study, perceptible changes took place in the radius of central corneal curvature, in which the horizontal and vertical radius altered virtually to the same degree. For this reason both radii are represented summarily

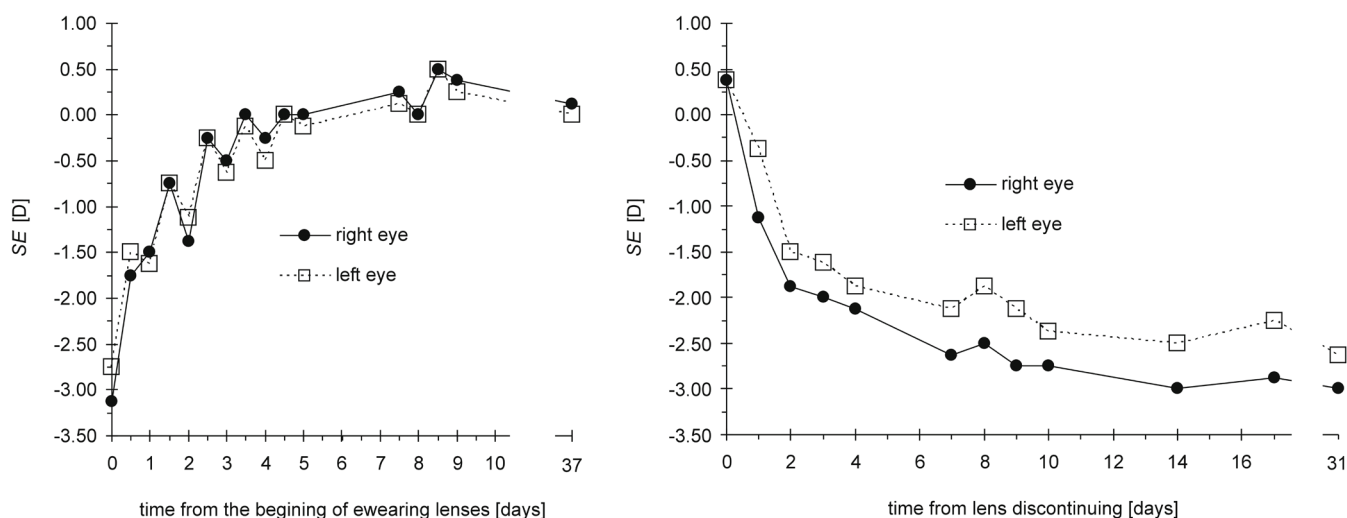


Fig. 1: Dependence of refraction (represented by a spherical equivalent SE) in time measured from the beginning of wearing lenses (left) and discontinuation of wearing lenses (right).

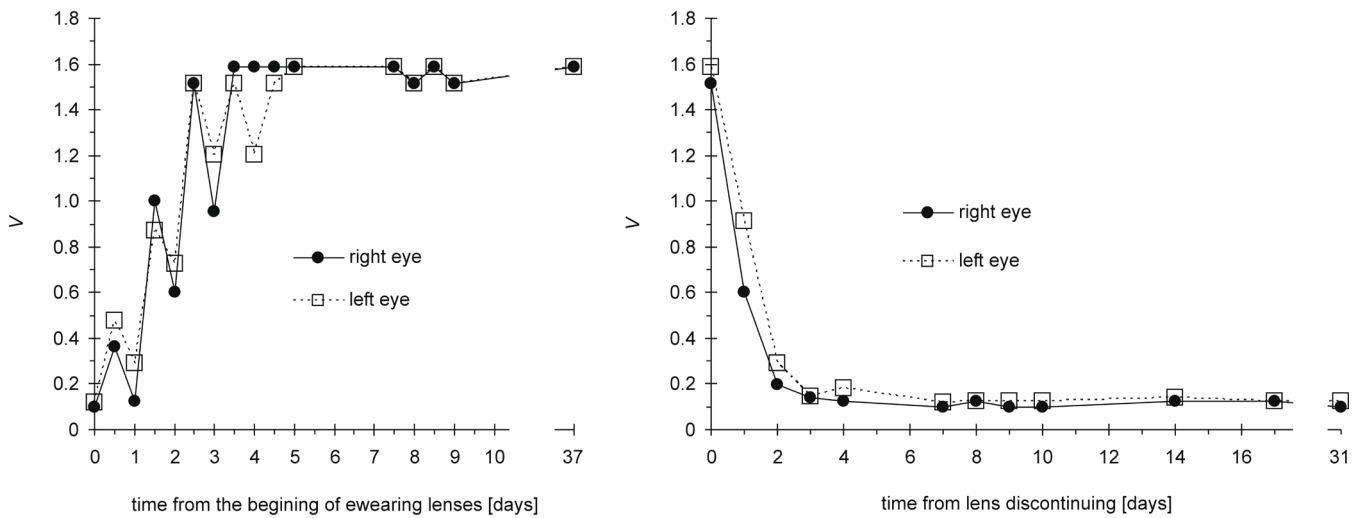


Fig. 2: Dependence of visual acuity V in time measured from the beginning of wearing lenses (left) and lens discontinuing (right).

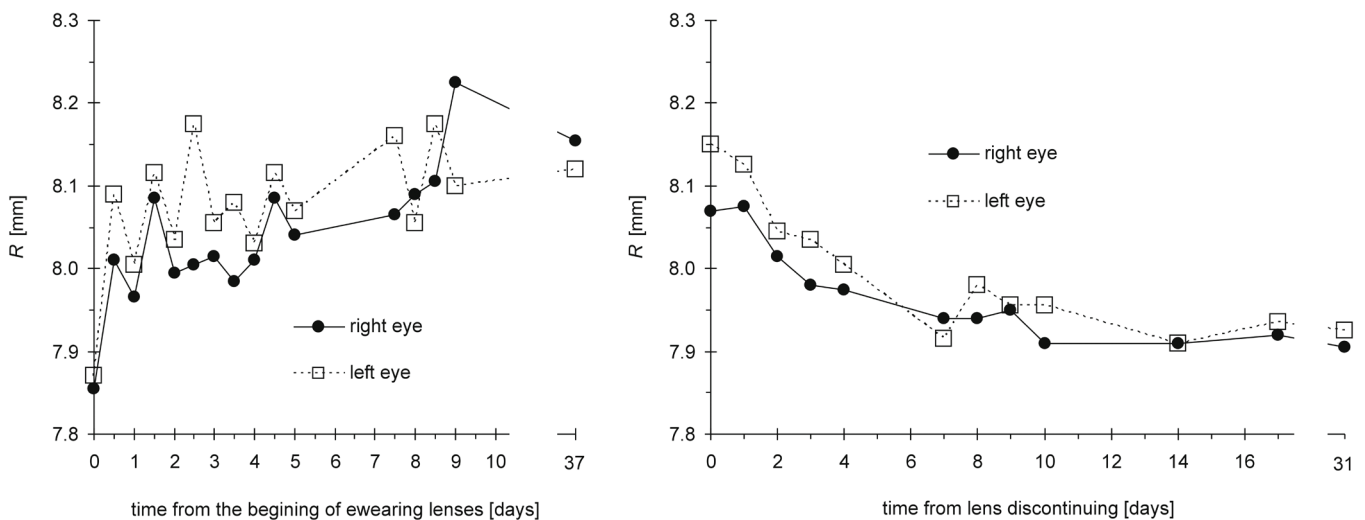


Fig. 3: Dependence of central corneal curvature radius R on time measured from the beginning of wearing lenses (left) and discontinuation of wearing lenses (right).

ly by their average R, the time course of which is illustrated in fig. 3. This increased from the beginning of wearing orthokeratological lenses after the 37th day from 7.86 mm to 8.08 mm in the right eye and from 7.87 mm to 8.15 mm in the left eye, i.e. the cornea was flattened in the centre. Larger changes took place progressively in the first 9 days, after which they stabilised. After discontinuation of wearing lenses there was a gradual return to the original values, in which the most marked change was during the first 10 days in the right eye and 14 days in the left eye, when virtually the original values were reached (Fig. 3). Changes in the overall shape of the cornea are illustrated by the topographical maps in fig. 4, where central flattening is distinctly perceptible, and conversely a reduction in the radius of curvature in the central periphery of the cornea (Fig. 4).

The time course of corneal thickness had a decreasing tendency in the first phase of observation, and conversely an increasing tendency after discontinuation of wearing the lenses (in the second phase). In this central corneal thickness

decreased after 3 months of wearing the lenses by 22  $\mu\text{m}$  in the right eye and by 20  $\mu\text{m}$  in the left eye. However, the determined changes are on the borderline of precision of measurement.

Upon correction there was a distinct increase in the observed higher-order aberrations. The size of the relevant RMS<sub>3,4</sub>, depending on time, is illustrated in fig. 5. Slightly higher values were measured in the morning, lower in the evening. After discontinuation of correction, the aberrations gradually returned to their original values over the course of approximately seven days, in which the largest reduction took place during the first two days without lenses (Fig. 5).

## DISCUSSION

It ensues from the results of previous studies that following the application of orthokeratological lenses it is possible to expect a minimally 80% reduction of the error [7, 18, 20, 23, 27] in the case of low to medium myopia, in which the

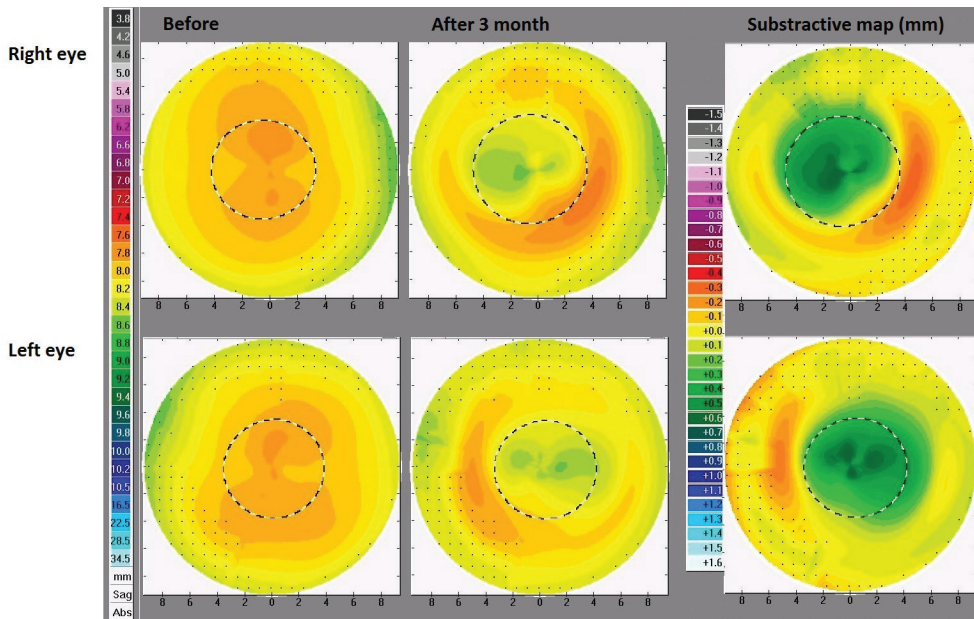


Fig. 4: Corneal topography maps of the sagittal curvature radius of the right and left eye before wearing of orthokeratological lenses (left), after 3 months of wearing (middle) and subtractive maps (right).

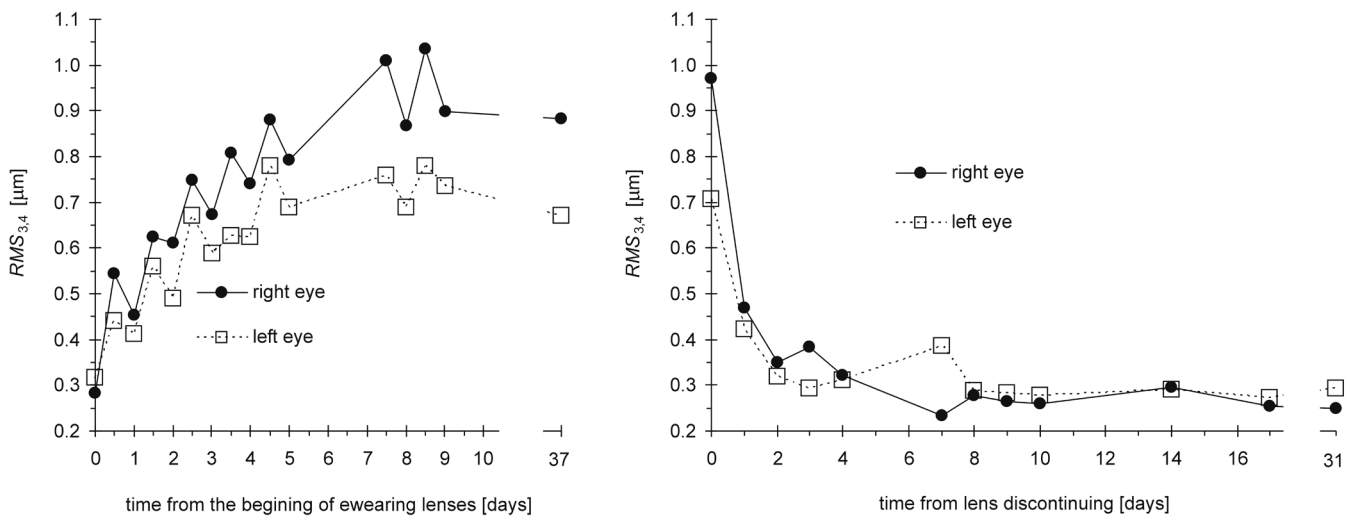


Fig. 5: Dependence of RMS corneal aberrations of 3rd and 4th order in time, measured from the beginning of wearing lenses (left) and discontinuation of wearing lenses (right).

largest reduction (up to 60%) takes place during the first night [10, 23, 24, 27]. The values stabilise at approximately around the 10th day. During the course of the day, regression (increase in dioptres) takes place by 0.5 D to 0.75 D in Caucasians (in Asians this regression is minimal) [16]. The studies have determined zero or only minimal correction of astigmatism [15, 23, 27]. It also ensues from the literature [9, 17] that in certain cases it is not possible to achieve ideal (full) correction for various reasons (for example due to the impossibility of precise centration of the lens, in the case of weak corneal reaction or excessively large refractive error). In the subject we observed it was confirmed that orthokeratological lenses are capable of fully correcting mild myopia, in which the onset of the effect is relatively rapid. The greatest reduction of the error took place during the first night (44 % in the right eye, 44.5% in the left eye) and from the fourth to the fifth day the effect lasted all day. From

the 9th day refraction was stable, in the morning spherical equivalent reached values of +0.25 D to +0.50 D, during the day this decreased by 0.25 D to 0.50 D, so in the evening refraction approximated 0 D. Changes in astigmatism were minimal. Vision after stabilisation of refraction was comparable with vision attained before the application of lenses, upon correction by eyeglasses. It has been demonstrated by several studies [4, 11, 16, 27] that after discontinuation of wearing lenses refraction returns to the original values. In this the speed of return depends on the original size of correction – the higher the correction, the faster the return [2]. The period of return ranges from 3 days to 8 weeks [2, 4, 11, 23]. In our case, after discontinuation of wearing lenses the error returned fully within fourteen days, in which the largest changes took place within the first two days. It ensues from the individual studies that through the influence of orthokeratological lenses a flattening of the central part

of the cornea takes place [15, 18, 19, 23], whilst in the central periphery corneal curvature becomes steeper [15]. The cornea is measurably flattened after 10 to 15 minutes of wearing orthokeratological lenses with open eyes [15, 24], and a more pronounced change then occurs after 8 hours of sleeping while wearing the lenses [19, 24], i.e. after the first sleep with the lenses. Stabilisation occurs after 10 days of wearing [23]. After discontinuation of wearing the lenses the cornea returns to its original shape within 1 week to 2 months, depending on the length of the period for which the lenses were worn, the design of the lens and the size of myopia [9]. Reduction of myopia takes place mainly thanks to flattening of the anterior surface of the cornea [8, 32]. In the study we conducted flattening of the centre of the cornea was actually observed in connection with the beginning of wearing lenses (the largest changes took place during the first nine days), with reduction of the radius of curvature taking place again after the discontinuation of wearing lenses. A return to the original values took place approximately after 10 days in the right eye and 14 days in the left eye. The course of the changes of corneal curvature copied the changes in subjective refraction. A slight reduction of central corneal thickness was also registered after 30 months of wearing lenses. The observations above are in accordance with other studies [1, 10, 13, 21, 31], which attribute this effect to the thinning of the epithelial layer caused by its realignment due to the influence of the action of the lens. In certain studies changes in the thickness of the stroma have also been observed [1, 21]. Changes of the anterior shape of the cornea may lead to an increase in higher-order aberrations, as has been demonstrated in a range of studies in the case of orthokeratological correction [3, 5, 15, 25]. In our case we concentrated on 3rd and 4th order aberrations. During application of the lenses these aberrations distinctly increased, which was subjectively manifested especially in twilight. Under worsened lighting conditions, widening of the pupil occurs and peripheral areas of the cornea are pronouncedly engaged in vision, which may become thickened due to the influence of the shift of epithelium from the centre, resulting in irregularities. These irregularities may then be the cause of the observed increase in aberrations. Specifically this concerned a halo and slight monocular double vision. Irregularities in the periphery are also attested to by the fact that photopic vision was normal, and subjective evaluation of vision under good lighting was excellent. After discontinuation of wearing the lenses, the largest decrease of the observed aberrations took place within

the first two days and the values returned to their original state after seven days, and it was within two days after discontinuation of wearing the lenses that a pronounced subjective improvement occurred in the case of vision in twilight. It was also determined that the values of higher-order aberrations reached lower values during the course of orthokeratological correction in the evening than in the morning. This is probably caused by the slight decline in the corrective effect during the course of the day, which can be substantiated by the above-mentioned daily changes in refraction. A higher increase in aberrations was determined in the right eye, and at the same time it was here that there was a higher refractive error. In accordance with the studies [5, 6] it is therefore possible to confirm that orthokeratological correction of a higher myopic defect leads to a larger increase in higher-order aberrations. The increase in aberrations may also be due to slight decentration of the lens during sleeping in an upward nasal direction, which is evident on the differential map (see fig. 4).

## CONCLUSION

It was verified that from a purely optical perspective, orthokeratological lenses represent an effective means for correction of mild myopia, which they are capable of fully correcting whilst attaining photopic vision comparable with correction by eyeglasses. In this process, all the corresponding shape and optical changes on the cornea are fully reversible. An optical disadvantage of this type of correction is the increase in higher-order aberrations, which are distinctly manifested upon widening of the pupil and therefore lower brightness. This may have a negative effect for example on driving motor vehicles or reading under worsened lighting conditions (twilight, mist, poor working lighting etc.). For this reason, this type of correction should not be recommended for people with high demands for vision under these conditions, and generally for people with wide pupils. Similar effects can be observed for example in the case of laser refractive surgery on the cornea. However, optical changes induced by orthokeratology are fully reversible. From a purely optical perspective, they therefore represent a fully adequate alternative to other types of correction for vision during the day.

## Thanks

*This study was supported by grant no. IGA\_PrF\_2016\_015 of the Faculty of Science, Palacký University in Olomouc.*

## LITERATURE

1. **Alharbi, A., Swarbrick, H.:** The effects of overnight orthokeratology lens wear on corneal thickness. *Invest Ophthalmol, Vis Sci*, 44; 2003: 2518–2523.
2. **Barr, J. T., Rah, M. J., Meyers, W. et al.:** Recovery of refractive error after corneal refractive therapy. *Eye & Contact Lens*, 30; 2004: 247–251.
3. **Gifford, P., Li, M., Lu, H. et al.:** Corneal versus ocular aberrations after overnight orthokeratology. *Optometry and Vision Science: Official Publication of the American Academy of Optometry*, 90; 2013: 439–447.
4. **Hiraoka, T., Okamoto, C., Ishi, Y. et al.:** Recovery of corneal irregular astigmatism, ocular higher-order aberrations, and contrast sensitivity after discontinuation of overnight orthokeratology. *Brit J Ophthalmol*, 93; 2009: 203–208.
5. **Hiraoka, T., Okamoto, C., Ishii, Y. et al.:** Mesopic contrast sensitivity and ocular higher-order aberrations after overnight orthokeratology. *Am J Ophthalmol*, 145; 2008: 645–655.
6. **Hiraoka, T., Okamoto, F., Kaji, Y. et al.:** Optical quality of the cornea after

- overnight orthokeratology. *Cornea*, 25; 2006: 59–63.
7. **Chan, B., Cho, P., Cheung, S. W.:** Orthokeratology practice in children in a university clinic in Hong Kong. *Clinical & Experimental Optometry*, 91; 2008: 453–460.
  8. **Chen, D., Lam, A. K. C., Cho, P.:** Posterior corneal curvature change and recovery after 6 months of overnight orthokeratology treatment. *Ophthalmic & Physiological Optics: The Journal of the British College of Ophthalmic Opticians (Optometrists)*, 30; 2010: 274–280.
  9. **Cho, P., Collins, M., Sawano, T.:** Orthokeratology Practice, A Basic Guide for Practitioners, European Academy of Orthokeratology, 2012, 132 s.
  10. **Choo, J., Caroline, P., Harlin, D.:** How does the cornea change under corneal reshaping contact lenses? *Eye & Contact Lens*, 30; 2004: 211–213.
  11. **Kobayashi, Y., Yanai, R., Chikamoto, T. et al.:** Reversibility of effects of orthokeratology on visual acuity, refractive error, corneal topography, and contrast sensitivity. *Eye & Contact Lens*, 34; 2008: 224–228.
  12. **Li, S., Kang, M., Wu, S. et al.:** Efficacy, Safety and Acceptability of Orthokeratology on Slowing Axial Elongation in Myopic Children by Meta-Analysis. *Current Eye Research*; 2015: 1–9.
  13. **Lian, Y., Shen, M., Jiang, J. et al.:** Vertical and horizontal thickness profiles of the corneal epithelium and Bowman's layer after orthokeratology. *Invest Ophthalmol Vis Sci*, 54; 2013: 691–696.
  14. **Liu YM, Xie P.:** The Safety of Orthokeratology - A Systematic Review. *Eye & Contact Lens*, 42; 2016: 35-42.
  15. **Lu, F., Simpson, T., Sorbara, L. et al.:** Malleability of the ocular surface in response to mechanical stress induced by orthokeratology contact lenses. *Cornea*, 27; 2008: 133–141.
  16. **Mountford, J., Ruston, D., Dave, T.:** Orthokeratology: Principles and Practice, Butterworth-Heinemann, 2004, 316 s.
  17. **Mountford, J.:** Retention and regression of orthokeratology with time. *International Contact Lens Clinic*, 25; 1998: 59–64.
  18. **Nichols, J. J., Marisch, M. M., Nguyen, M. et al.:** Overnight orthokeratology. *Optometry and Vision Science: Official Publication of The American Academy of Optometry*, 77; 2000: 252–259.
  19. **Owens, H., Garner, L. F., Craig, J. P. et al.:** Posterior Corneal Changes with Orthokeratology. *Optometry & Vision Science*, 81; 2004: 421–426.
  20. **Potapova, N., Wang, G., Haji, S. et al.:** Corneal topography in corneal refractive therapy (CRT): a 1-month follow-up. *Eye & Contact Lens*, 30; 2004: 166–168.
  21. **Reinstein, D. Z., Gobbe, M., Archer, T. J. et al.:** Epithelial, stromal, and corneal pachymetry changes during orthokeratology. *Optometry and Vision Science: Official Publication of the American Academy of Optometry*, 86; 2009: 1006–1014.
  22. **Si, J., Tang, K., Bi, H. et al.:** Orthokeratology for Myopia Control: A Meta-analysis. *Optometry and Vision Science: Official Publication of the American Academy of Optometry*, 92; 2015: 252–257.
  23. **Sorbara, L., Fonn, D., Simpson, T. et al.:** Reduction of myopia from corneal refractive therapy. *Optometry and Vision Science: Official Publication of the American Academy of Optometry*, 82; 2005: 512–518.
  24. **Sridharan, R., Swarbrick, H. A.:** Corneal response to short-term orthokeratology lens wear. *Optometry and Vision Science: Official Publication of the American Academy of Optometry*, 80; 2003: 200–206.
  25. **Stillitano, I. G., Chalita, M. R., Schor, P. et al.:** Corneal changes and wavefront analysis after orthokeratology fitting test. *American Journal of Ophthalmology*, 144; 2007: 378–386.
  26. **Sun, Y., Xu, F., Zhang, T. et al.:** Orthokeratology to control myopia progression: a meta-analysis. *PloS One*, 10; 2015.
  27. **Swabrick, H. A.:** Orthokeratology review and update. *Clinical & Experimental Optometry*, 89; 2006: 124–143.
  28. **Swarbrick, H. A., Wong, G., O'Leary, D. J.:** Corneal Response to Orthokeratology. *Optometry & Vision Science*, 75; 1998: 791–799.
  29. **Thibos, L. N., Applegate, R. A., Schwiegerling, J. T. et al.:** Standards for Reporting the Optical Aberrations of Eyes. *J Refract Surg*, 18; 2002: 265-660.
  30. **Thibos L. N., Himebaugh N. L., Coe C. D.:** Wavefront Refraction. In: Benjamin JW, ed.: *Borish's Clinical Refraction*. 2nd Edition. Butterworth-Heinemann, 2006, s. 765-789.
  31. **Wang, J., Fonn, D., Simpson, T. L. et al.:** Topographical thickness of the epithelium and total cornea after overnight wear of reverse-geometry rigid contact lenses for myopia reduction. *Investigative Ophthalmology & Visual Science*, 44; 2003: 4742–4746.
  32. **Yoon, J. H., Swarbrick, H. A.:** Posterior corneal shape changes in myopic overnight orthokeratology. *Optometry and Vision Science: Official Publication of the American Academy of Optometry*, 90; 2013: 196–204.