

# COMBINATION OF INTRAVITREAL CORTICOSTEROID WITH ANTI-VEGF IN MACULAR EDEMA SECONDARY TO RETINAL VEIN OCCLUSION

Valášková J., Popov I., Krásnik V.

Department of Ophthalmology, Faculty of Medicine, Comenius University and University Hospital, Bratislava, Head: doc. MUDr. Vladimír Krásnik, PhD.

*The authors of the study declare that no conflict of interest exists in the compilation, theme and subsequent publication of this professional communication, and that it is not supported by any pharmaceuticals company.*

## SUMMARY

**Purpose:** functional and anatomical results after combination of intravitreal dexamethasone implant with anti-VEGF bevacizumab in macular edema secondary to retinal vein occlusion.

**Methods:** Retrospective analysis of 50 patients, average age 72 years, 15 men and 35 women. Inclusion criteria for treatment were retinal vein occlusion, best corrected visual acuity (BCVA) more than 20/200 and macular edema more than 250  $\mu\text{m}$ . Algorithm of treatment was dexamethasone, anti-VEGF (bevacizumab), dexamethasone. Application of anti-VEGF bevacizumab was in interval between two applications of dexamethasone, for the first time in every patient. If there were nonperfusion areas on fluoresceine angiography (FA), or ischemia on slit lamp, repeatedly. Patients observed for 12 months at least. This cohort included patients with branch retinal vein occlusion together with central retinal vein occlusion. This is an evaluation of nonperfusion areas based on FA, BCVA, macular edema on optical coherence tomography (OCT) and number of reapplication of anti-VEGF bevacizumab. Observed adverse effects are elevation of intraocular pressure and number of patients who underwent cataract surgery.

**Results:** The gain of 8 letters in 1<sup>st</sup> month after 1<sup>st</sup> application of dexamethasone, central retinal thickness (CRT) reduced from 512  $\mu\text{m}$  to 318  $\mu\text{m}$  in average. 33 patients get 1, 3 patients get 2 and 14 patients 3 injections of bevacizumab. On the day of 2<sup>nd</sup> application of dexamethasone, in 7<sup>th</sup> month in average, the CRT increased on 465  $\mu\text{m}$ , and 1<sup>th</sup> month after, the gain from the baseline was 10 letters and CRT reduced on 380  $\mu\text{m}$ . All the patients were phakic at the baseline, 18 (36 %) patients underwent cataract surgery with intraocular lens implantation. Transient elevation of intraocular pressure in 15 (30 %) eyes, treated by local therapy.

**Conclusion:** Combination of intravitreal dexamethasone implant with anti-VEGF bevacizumab is functionally and anatomically effective.

**Key words:** retinal vein occlusion, macular edema, dexamethasone, bevacizumab

Čes. a slov. Oftal., 73, 2017, No. 5–6, p. 183–188



MUDr. Jela Valášková  
Klinika Oftalmologie LF UK a UNB  
Nem. Ružinov, Ružinovská 6,  
826 06 Bratislava, SR  
e-mail: jelavalasek@hotmail.com

## INTRODUCTION

After diabetic retinopathy, retinal vein occlusion is the second most common vascular disorder of the retina (27).

The prevalence of retinal vein occlusion (RVO) is stated in population studies within a range from 0.7% to 1.6% (2, 13), and increases with age (15). Worldwide 16.4 million adults suffer from this disorder, of whom 2.5 million with central retinal vein occlusion (CRVO) and 13.9 million with branch retinal vein occlusion (BRVO) (10, 23).

The main general risk factors for branch, central and hemiretinal vein occlusion (HRVO) were identified in the study The Eye Disease Case – Control Study Group (21, 22). Among the most common are systemic hypertension, cardiovascular disease and diabetes mellitus (21, 22). The ocular risk factors for RVO include glaucoma, ocular hypertension and sclerotic changes in the blood vessels of the retina in the place of crossing of the artery and vein (7, 8, 33).

The majority of the theories of the pathophysiology of retinal vein occlusion are based on Virchow's triad (1856): venous stasis, dysfunction of the endothelium and thrombophilic state. The mechanisms of occlusion are intercon-

nected, one factor mostly does not suffice, a combination thereof is necessary. Upon CRVO the risk location is the crossing of the artery and the central retinal vein in the shared casing of the adventitia across the lamina cribrosa sclerae (LCS) (24). In the case of BRVO the anatomical specifics of arteriovenous crossing and secondary sclerotic changes of the arterial wall clarify why precisely this localisation is critical for the through passage of the venous lumen (25). Primarily inflammatory process in the wall of the vein and hypercoagulable state is etiologically less common. Despite this, the pathogenesis of origin of macula edema secondary to retinal vein occlusion is unclear. The majority of authors accentuate high intracapillary pressure (12) in the genesis, which acts as an obstacle to capillary perfusion, leading to the onset of ischaemia. Ischaemia causes increased production of vascular endothelial growth factor (VEGF) (16, 32), new formation of blood vessels and transudation of fluid from the abnormally permeable paramacular network. Ischaemia induces the formation and secretion of several inflammatory and angiogenic factors, interleukins (IL-1B, IL-6), tumour of necrotising factor and prostaglandins (17, 28, 30, 32). Experimental studies have demonstrated that the

increase of VEGF after the onset of occlusion is very rapid and transitional, with a return of VEGF concentration to the original values within the course of a few days, but that the growth of other of the above-stated inflammatory factors is extended to several weeks (20).

The prognosis depends on the length of duration of the pathology, on the form and extent of the circulatory disorder and reperfusion. The more significant the extent of the circulatory disorder, the more pronounced the macular edema and ischaemia, which corresponds to the decrease in central visual acuity. With regard to the form of the pathology it is important to assess the extent of ischaemia on the basis of FA. The non-ischaemic form of retinal vein occlusion is a benign pathology with a medium-severe impairment of visual functions as a consequence of macular edema and a low risk of the occurrence of neovascularisation. The ischaemic form of retinal vein occlusion is a serious, sight-threatening pathology, with a high probability of the formation of neovascularisations. A transition of the non-ischaemic to ischaemic form is stated in 5% to 33% of cases (4, 9, 19, 31). Extensive haemorrhages on the retina frequently render impossible a decision on the degree of capillary non-perfusion, some authors indicate this group as "unclassifiable" occlusions. As many as 83% of these occlusions develop into the ischaemic form (4, 31).

The current therapeutic possibilities incorporate intravitreally applied pharmaceuticals (ranibizumab, aflibercept, dexamethasone implant, triamcinolone – off label and bevacizumab – off label), surgical solution and laser. The effectiveness of laser treatment was demonstrated by the Branch Vein Occlusion Study Group (BVOS" (1) by the method of reducing the expression of growth and angiogenic factors (1, 26). With regard to the possible transition of the non-ischaemic to ischaemic form and the risk of appearance of ischaemic zones on the periphery of the retina, which are not diagnosable using regular FA with a scope of 30 to 50° (5-15% of the surface of the retina), preventive laser coagulation of the periphery of the retina is purposeful in the case of CRVO (11).

The aim of our retrospective analysis was to evaluate the functional and anatomical result in a cohort of patients treated with a combination of two different intravitreal pharmaceuticals.

## METHOD

The retrospective analysis included 50 patients treated with a combination of a depot corticosteroid with bevacizumab from January 2012 to September 2016. The initial criteria for commencing treatment was diagnosis of RVO, BCVA 20/200 to 20-32 and macular edema >250 µm.

### Procedure

In the majority of patients the ocular and personal anamnesis was recorded, a complete ophthalmological examination was conducted, as well as an internal examination including haematological and haemocoagulation test and USG of the carotid arteries. After approval of the treatment

by the insurance company, the patients were treated according to the algorithm of dexamethasone – bevacizumab 1 to 3 injections – dexamethasone. The second application of dexamethasone was at the earliest 6 months after application of the first injection of dexamethasone.

### Characteristics of cohort

The cohort included 50 patients, consisting of 35 women and 15 men aged from 54 to 81 years, in whom the average age was 72 years. There were 29 patients with BRVO (58%) and 21 with CRVO (42%). The duration of the pathology was within a range from 1 month to 12 months. Initial BCVA was within the range of 20/200 to 20/32 and macular edema larger than 250 µm. Fluorescence angiography was conducted on all patients with BRVO, none of the patients had ischaemic zones larger than 5 papillary diameters. Fluorescence angiography on patients with CRVO was more difficult to evaluate due to intraretinal haemorrhages, which covered the potential non-perfusion zones.

## RESULTS

One month after the 1st application of dexamethasone we recorded a gain of an average of 8 letters. For the BRVO group this was 9 letters and for the CRVO group 7 letters on average. CRT was reduced from an average thickness of 512 µm to 318 µm, for the BRVO group from 376 µm to 288 µm, for the CRVO group from 648 µm to 550 µm. We subsequently applied 1 to 3 injections of bevacizumab on the basis of the ophthalmoscopic finding and the scope of non-perfusion zones on FA. Thirty patients received 1 injection, 3 patients 2 injections and 14 patients 3 injections of bevacizumab in the 4th to 6th month at monthly intervals. During the second application of dexamethasone, on average in the 7th month, CRT reached an average of 465 µm, in the group with BRVO 380 µm and in the group with CRVO 550 µm. One month after the 2nd application of dexamethasone we had an average gain of 10 letters, specifically 11 letters in the BRVO group and 9 letters in the CRVO group. CRT was reduced to an average of 380 µm, for the BRVO group to 344 µm and for the CRVO group to 416 µm (Graphs 1, 2, 3, 4, 5, 6). At the beginning of treatment all patients were phakic, during the course of treatment 18 (36%) patients underwent cataract surgery. A temporary increase in intraocular pressure with local treatment was recorded in 15 (30%) patients.

## DISCUSSION

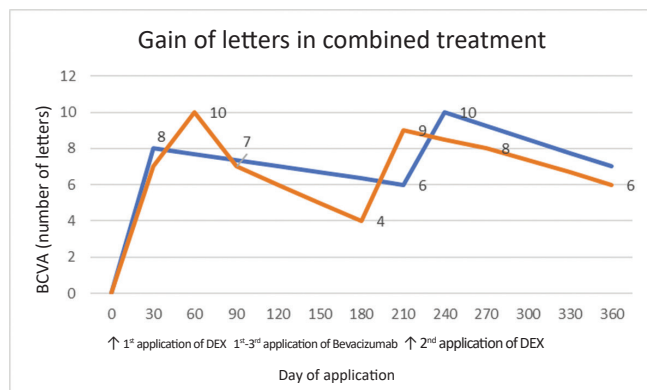
Ozurdex® (Allergan, Irvine, CA, USA) was approved by the FDA (Food and Drug Administration) in 2009. It is a corticosteroid, dexamethasone, with 3x higher effectiveness than triamcinolone acetate. Its disadvantage is the extremely rapid half-life of decay – 5.5 hours in the vitreous body, and for this reason it is manufactured in the form of an intravitreal implant, a biodegradable rod containing 0.7 mg of active substance, which has an extended time of effective-

ness. Over the course of time, the polymer matrix of the rod opens porously until disintegration, which enables the release of the active substance for a period of up to 6 months, with the highest concentration during the 2nd month (5). The safety and effectiveness of dexamethasone was evaluated in the GENEVA study – The Global Evaluation of Implantable Dexamethasone in Retinal Vein Occlusion With Macular Edema (5). Ozurdex® improves visual functions 30 days after the commencement of treatment, persisting for more than 90 days, it is well tolerated and has significantly less adverse effects in comparison with triamcinolone acetate (6).

Bevacizumab (Avastin®, Genentech Inc.) is a 149 kDa recombinant humanised monoclonal anti-VEGF antibody, which binds all isoforms of VEGF-A. It is used off-label for the treatment of macular edema secondary to RVO, diabetic macular edema and age-related macular degeneration. It prevents the increased release of VEGF-A and PEDF, and reduces the release of IL-1B (3). The effect of bevacizumab on macular edema secondary to RVO has been evaluated in several studies (14, 29).

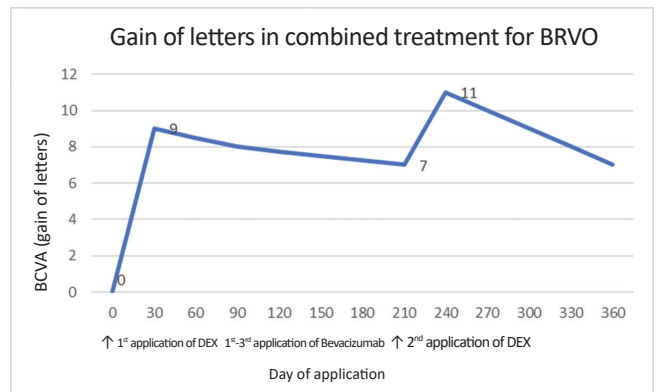
In the Geneva study (6), upon observation and treatment of patients with Ozurdex® over the course of 12 months, there was a loss of 6 letters on average between the 2 applications of dexamethasone. In our cohort we were able to reduce this loss with the aid of anti-VEGF bevacizumab, through which we attained a loss of only 2 letters on average between the two applications of Ozurdex®, and at the same time we attained a higher gain of letters after the 2nd application in comparison with the commencement of treatment. A similar effect in combined therapy has also been achieved by other authors in their cohorts (14, 29).

Mayer et al. (14) compared a cohort of patients (64 eyes) with RVO treated only with Oxurdex® with a cohort of patients treated with the algorithm: 3 injections of bevacizumab – Ozurdex® – Ozurdex® according to requirement. The

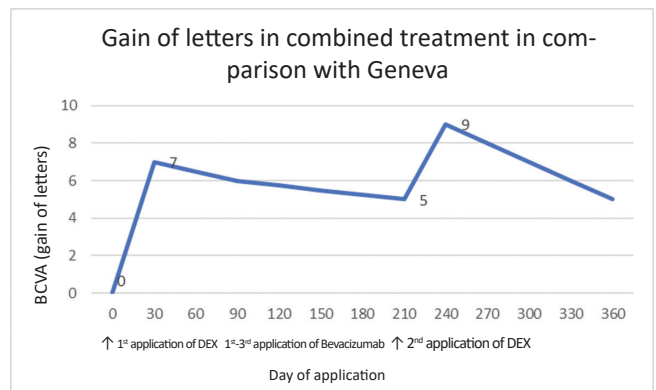


Graph 1 Gain of letters upon combined treatment for RVO in comparison with the Geneva study

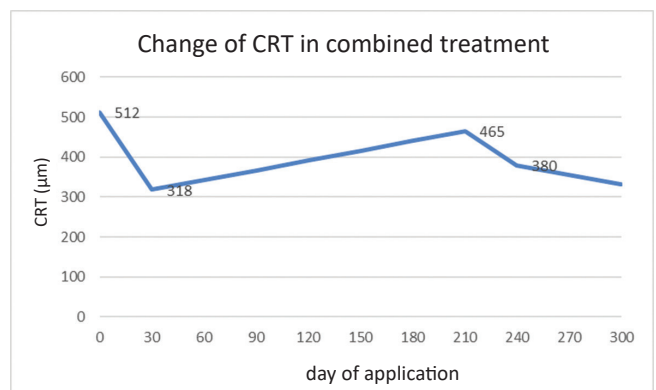
Note: Comparison of the Geneva study and combined treatment, the blue curve illustrates the Geneva study, the red curve combined treatment. The 1<sup>st</sup> application of dexamethasone was on day zero, 1 to 3 applications of bevacizumab were administered intravitreally between the 3rd and 6th month from day zero. The second application of dexamethasone was administered on average within the 7<sup>th</sup> month



Graph 2 Gain of letters upon BRVO during combined treatment



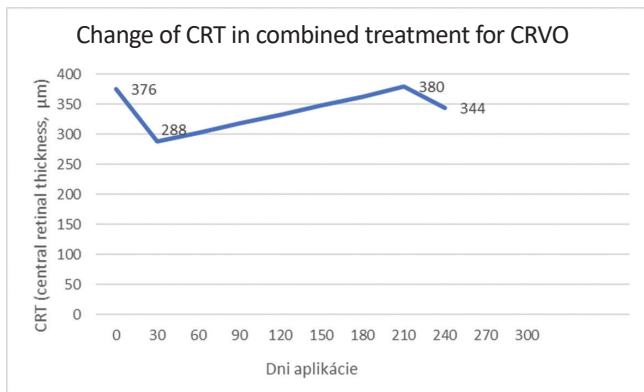
Graph 3 Gain of letters upon CRVO during combined treatment



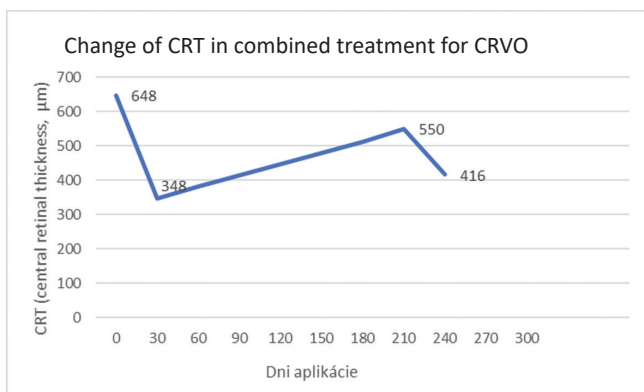
Graph 4 Change of CRT in combined treatment

Note: changes of retinal thickness during the course of combined treatment in our observed cohort. On day 0 CRT was on average 512 µm, after the first month of intravitreal treatment there was a reduction to 318 µm. During the following six months average CRT increased to 465 µm. CRT was reduced to 380 µm 1 month after the 2nd application of dexamethasone.

aim was to determine BCVA in the 12th month. They determined that upon combined therapy there is a higher gain of letters in comparison with monotherapy by Ozurdex® (9.8 letters compared to 6.6 letters in the case of CRVO, 9.4 letters as against 7.8 letters in the case of BRVO). Recurrent edema following the 1st application of Ozurdex® occurred



Graph 5 Change of CRT in combined treatment for BRVO



Graph 6 Change of CRT in combined treatment for CRVO

in the group with monotherapy after 3.2 months, and upon combined treatment after 3.7 months. Increased intraocular pressure was determined in 40%, and progression of cataract requiring surgery in 50% of eyes, which was probably connected with the 3 applications of Ozurdex®.

Singer et al. (14) evaluated a cohort of patients (34 eyes) with RVO (35% CRVO, 65% BRVO). The patients were treated with the algorithm bevacizumab – after 2 weeks Ozurdex® - after recurrence of edema Ozurdex®. In 97% of patients the maximum gain was 25 letters, in which as many as 64% of patients achieved a gain of 15 letters during the course of treatment. The study demonstrated the effectiveness of combined therapy in comparison with monotherapy by Ozurdex®.

Adverse effects of Ozurdex® were evaluated in the

GENEVA study. During the GENEVA study, the occurrence of cataract was recorded in 29.8% after the 2nd application of Ozurdex®, in our cohort 36% of patients underwent cataract surgery during the course of treatment, which is connected not only with the application of Ozurdex® but also with the average age of the cohort, i.e. 72 years, as well as with the presence of opacities of the lens at the beginning of treatment. Increased intraocular pressure was recorded in 25.5% of patients during the GENEVA study. On our cohort we recorded 30% of patients with increased intraocular pressure. In the studies published to date, various percentages of increased intraocular pressure requiring treatment are recorded. The evaluation of this adverse effect requires larger cohorts and long-term observation.

At present several studies are focusing on the effect of repeated applications of Ozurdex®. In the Remido 2 Study, with an average of 2.6 applications of Ozurdex® (max. 6 applications), Pommier recorded a gain of > 15 letters in 58.6% of patients, while resorption of macular edema was achieved in 51.1% of patients (18). The indication restriction in the Slovak Republic enables the application of a depot corticosteroid – Ozurdex® 2x within a 6 monthly interval.

## CONCLUSION

Retinal vein occlusion is a serious, sight-threatening pathology. As a consequence of its multifactorial etiology and the complex pathogenesis, causal therapy is not known. Treatment must take into account not only the local and general clinical finding, but also the adverse effects of intravitreal pharmaceuticals and our possibilities from the perspective of paying for the medication. Treatment by means of intravitreally administered drugs has limits – the clinical finding and indication restrictions of individual pharmaceuticals. In this cohort of patients we demonstrated that a group of patients exists for whom combined therapy is suitable from an anatomical and functional perspective. At the same time, we wish to point to the fact that a relatively large section of patients require long-term treatment. Clinical practice shows that a 6 monthly interval and 2 applications of Ozurdex® (indication restriction and payment in the Slovak Republic) are often insufficient, and in the second year there remains a significant percentage of eyes with chronic macular edema, which would be suitable for continuation of therapy by corticosteroids.

## LITERATURE

1. Branch Vein Occlusion Study Group. Argon laser scatter photocoagulation for prevention of neovascularization and vitreous haemorrhage in branch vein occlusion. A randomized clinical trial. *Arch Ophthalmol*, 104(1); 1986: 34–41.
2. Cugatti, S., Wang, J.J., Roctchina, E. et al.: Ten-year incidence of retinal vein occlusion in an older population: the Blue Mountains Eye Study. *Arch Ophthalmol*, 124(5); 2006: 726–732.
3. Drechsler, F., Köferl, P., Hollborn, M. et al.: Effect of intravitreal anti-vascular endothelial growth factor treatment on the retinal gene expression in acute experimental central retinal vein occlusion. *Ophthalmic Res*, 47(3); 2012: 157–162.
4. Glacet-Bernard, A., Coscas, G., Chabanel, A. et al.: Prognostic factors for retinal vein occlusion: prospective study of 175 cases. *Ophthalmology*, 103; 1996: 551–60.
5. Haller, J.A., Bandello, F., Belfort, R. Jr. et al.: OZURDEX GENEVA Study Group, Randomized, sham-control trial of dexamethasone intravitreal implant in patients with macular edema due to retinal vein occlusion. *Ophthalmology*, 117(6); 2010: 1134–1146.
6. Haller, J.A., Bandello, F., Belfort, R. Jr. et al.: Ozurdex GENEVA Study Group: Dexamethasone intravitreal implant in patients with macular edema

- related to branch or central retinal vein occlusion twelve-month study results. *Ophthalmology*, 118(12); 2011: 2453–60.
7. **Hariprasad, S.M.(Ed):** Management of Retinal Vein Occlusion. Current Concepts, Slack, 2014, 5 p.
  8. **Hayreh, S.S., Zimmerman, M.B., Beri, M. et al.:** Intraocular pressure abnormalities associated with central and hemicentral retinal vein occlusion. *Ophthalmology*, 111; 2004: 133–41.
  9. **Hayreh, S.S., Zimmermann, M.B., Podhajsky, P.:** Incidence of various types of retinal vein occlusion and their recurrence and demographic characteristics. *Am J Ophthalmol*, 117(4); 1994: 429–41.
  10. **Ho, M., Liu, D.T., Lam, D.S. et al.:** Retinal vein occlusions, from basics to the latest treatment. *Retina*, 36(3); 2016: 432–48.
  11. **Ip, M.S., Scott, I.U., VanVeldhuisen, P.C. et al.:** The SCORE Study Research Group. A Randomized Trial Comparing the Efficacy and Safety of Intravitreal Triamcinolone With Observation to Treat Vision Loss Associated With Macular Edema Secondary to Central Retinal Vein Occlusion The Standard Care vs Corticosteroid for Retinal Vein Occlusion (SCORE) Study Report 5. *Arch Ophthalmol*, 127(9); 2009: 1101–1114.
  12. **Jalkh, A.E., Avila, P.M., Zakka, K.A. et al.:** Chronic macular oedema in retinal branch occlusion: role of laser photocoagulation. *Ann Ophthalmol*, 16(6); 1984: 532–3.
  13. **Klein, R., Klein, B.E., Moss, S.E. et al.:** The epidemiology of retinal vein occlusion: the Beaver Dam Eye Study. *Trans Am Ophthalmol Soc*, 98; 2000: 133–41.
  14. **Mayer, W.J., Wolf, A., Kernt, M. et al.:** Twelve-month experience with Ozurdex for the treatment of macular edema associated with retinal vein occlusion. *Eye (Lond)*, 27(7); 2013: 816–22.
  15. **Mitchell, P., Smith, W., Chang, A.:** Prevalence and associations of retinal vein occlusion in Australia. The Blue Mountains Eye Study. *Arch Ophthalmol*, 114(10); 1996: 1243–7.
  16. **Noma, H., Funatsu, H., Harino, S. et al.:** Vitreous inflammatory factors in macular edema with central retinal vein occlusion. *Jpn J Ophthalmol*, 55(3); 2011: 248–55.
  17. **Noma, H., Funatsu, H., Mimura, T. et al.:** Vitreous levels of interleukin-6 and vascular endothelial growth factor in macular edema with central retinal vein occlusion. *Ophthalmology*, 116(1); 2009 Jan: 87–93.
  18. **Pommier, S., Meyer, F., Guigou, S. et al.:** Long-Term Real-Life Efficacy and Safety of Repeated Ozurdex® Injections and Factors Associated with Macular Edema Resolution after Retinal Vein Occlusion: The REMIDO 2 Study. *Ophthalmologica*, 236(4); 2016: 186–192.
  19. **Quinlan, P.M., Elman, M.J., Bhatt, A.K. et al.:** Natural course of central retinal vein occlusion. *Am J Ophthalmol*, 110(2); 1990: 118–23.
  20. **Rehak, M., Hollborn, M., Iandiev, I. et al.:** Retinal gene expression and Müller cell responses after branch retinal vein occlusion in the rat. *Invest Ophthalmol Vis Sci*, 50(5); 2009: 2359–67.
  21. Risk factors for branch retinal vein occlusion. The Eye Disease Case – Control Study Group. *Am J Ophthalmol*, 116(3); 1993: 286–296.
  22. Risk factors for central retinal vein occlusion. The Eye Disease Case – Control Study Group. *Arch Ophthalmol*, 114(5); 1996: 545–554.
  23. **Rogers, S., McIntosh, R.L., Cheung, N. et al.:** International Eye Disease Consortium: The prevalence of retinal vein occlusion: pooled data from population studies from the United States, Europe, Asia, and Australia. *Ophthalmology*, 117(2); 2010: 313–9.
  24. **Řehák, J., Řehák, M.:** Venózní okluze sítnice, Grada Publishing, 2011, 58 s.
  25. **Řehák, J., Řehák, M.:** Venózní okluze sítnice, Grada Publishing, 2011, 59 s.
  26. **Scott, I.U., Ip, M.S., VanVeldhuisen, P.C. et al.:** SCORE Study Research Group: A randomized trial comparing the efficacy and safety of intravitreal triamcinolone with standard care to treat vision loss associated with macular edema secondary to branch retinal vein occlusion: the Standard Care vs Corticosteroid for Retinal Vein Occlusion (SCORE) Study report 6. *Arch Ophthalmol*, 127; 2009: 1115–28.
  27. **Shahid, H., Hossain, P., Amoaku, W.M.:** The management of retinal vein occlusion: is interventional ophthalmology the way forward? *Br J Ophthalmol*, 90(5); 2006: 627–39.
  28. **Shimura, M., Nakazawa, T., Yasuda, K. et al.:** Visual prognosis and vitreous cytokine levels after arteriovenous sheathotomy in branch retinal vein occlusion associated with macular oedema. *Acta ophthalmologica*, 86(4); 2008: 377–84.
  29. **Singer, M.A., Bell, D.J., Woods, P. et al.:** Effect of combination therapy with bevacizumab and dexamethasone intravitreal implant in patients with retinal vein occlusion. *Retina*, 32(7); 2012: 1289–94.
  30. **Suzuki, Y., Nakazawa, M., Suzuki, K. et al.:** Expression profiles of cytokines and chemokines in vitreous fluid in diabetic retinopathy and central retinal vein occlusion, 55(3); 2011: 256–63.
  31. The Central Vein Occlusion Study Group M report. Evaluation of grid pattern photocoagulation for macular edema in central retinal vein occlusion. *Ophthalmology*, 102; 1995: 1425–33.
  32. **Yoshimura, T., Sonoda, K.H., Sugahara, M. et al.:** Comprehensive analysis of inflammatory immune mediators in vitreoretinal diseases. *PLoS One*, 4(12); 2009: e8158.
  33. **Zhao, J., Sastry, S.M., Sperduto, R.D. et al.:** Arteriovenous crossing patterns in branch retinal vein occlusion. The Eye Disease Case-Control Study Group. *Ophthalmology*, 100(3); 1993: 423–8.