

ACUTE MYOPIA WITH ELEVATION OF INTRAOCULAR TENSION AS AN ADVERSE SIDE EFFECT OF ANTIDEPRESSANT MEDICATION

Hrčková L.¹, Mojžiš P.^{1,2}, Žiak P.²

¹Department of Ophthalmology, Havlíčkův Brod Hospital

²Department of Ophthalmology, Jessenius Faculty of Medicine in Martin, Comenius University Bratislava.

Department of Ophthalmology, Havlíčkův Brod Hospital, Chief Physician: MUDr. Peter Mojžiš Ph.D., FEBO

The authors of the study declare that no conflict of interest exists in the compilation, theme and subsequent publication of this professional communication, and that it is not supported by any pharmaceuticals company.



MUDr. Lucia Hrčková
Oční oddělení nemocnice Havlíčkův Brod
Husova 2624, 580 22, Havlíčkův Brod
lucia.hrckova@onhb.cz

SUMMARY

Case-report: The author presents case report of acute induced myopia with mild intraocular pressure elevation by young patient using trazodone. The presentation is completed with the documentation of anterior chamber depth and angle changes by using and after discontinuation of trazodone.

Conclusion: Acute transient myopia may be rare side effect of systemic used drugs in predisposed patients. Early and correct diagnosis is very important, because induced myopia may be accompanied by acute angle-closure glaucoma or supraciliary choroidal effusion. The only correct treatment in this case is discontinuation of the drug.

Key words: acute angle-closure glaucoma, acute myopia, antidepressants, side effects, trazodone

Čes.a slov. Oftal., 74, 2018, No.2, p. 68-72

INTRODUCTION

Acute induced myopia occurs in rare cases as an adverse side effect of systemically administered pharmaceuticals, most frequently sulfonamides [1]. A number of cases of transient, therapy-induced myopia have been published, frequently linked with the occurrence of acute angle-closure glaucoma [5, 9, 10, 13] or the occurrence of supraciliary choroidal effusion [9, 13]. The mechanism of origin is explained by means of a swelling of the ciliary body, and its rotation with a subsequent shift of the lens-iris diaphragm in a forward direction [7, 12].

Trazodone is an antidepressant which belongs to the group of third generation monoamine reuptake inhibitors. It is an antagonist of the post-synaptic serotonin 5-HT receptors and at the same time an inhibitor of serotonin reuptake. It also manifests a peripheral alpha-adrenolytic effect by means of a blockade of the alpha1-adrenergic receptors. It is used most frequently for the treatment of depression, anxiety disorders and sleep disorders. Its adverse side effects include drowsiness, increased anxiety, dizziness, headaches, nausea, nocturnal hallucinations, reduced libido and others.

METHOD

Our presentation analyses in detail a case report of a patient with acute myopia induced by antidepressant therapy. The case report includes photographs of the anterior segment of the eye and quantified results of biometric and refractive measurement.

CASE REPORT

A 34-year-old patient, a professional lorry driver, hyperten-

nic, on a course of antidepressant therapy, upon waking in the night experienced bilateral deterioration of distance vision, which escalated during the course of the following day. The patient's long-term antidepressant therapy of 20 mg citalopram 1x per day had been supplemented 13 days before the occurrence of the complaints by 50 mg trazodone 1x per day. The patient's ocular anamnesis was negative. Best corrected visual acuity was 1.0 with -4.0 Dpt in the right eye and 1.0 with -5.0 Dpt in the left eye, intraocular pressure of 22 torr in the right eye and 23 torr left eye. The results of cycloplegic refractometer examination did not differ fundamentally from the result of natural measurement. Examination on a slit lamp demonstrated bilateral shallowing of the anterior chamber of the eye (Fig. 1A and 1C) and constriction of the chamber angle. The other parameters of the anterior segment, including pupil width, photoreaction and also biomicroscopic fundus examination were bilaterally physiological.

The axial length of the right eyeball was 24.07 mm, with depth of the anterior chamber 2.97, in the left eye the axial length of the eyeball was 24.0 mm, with depth of the anterior chamber 2.84 mm. With regard to the development of nausea and headache during the course of examination, an internal and neurological examination was also ordered for the patient, including CT of the brain. The results of the examination were without significant pathology. At the same time, an internal conciliary examination excluded the presence of diabetes as a potential factor in myopia. Discontinuation of trazodone was indicated for the patient, with the result that 5 days after discontinuation the patient's vision improved to 1.0 naturally bilaterally. The anterior chamber deepened to 3.32 mm in the right eye (Fig. 1B) and 3.36 mm in the left eye (Fig. 1D). Widening

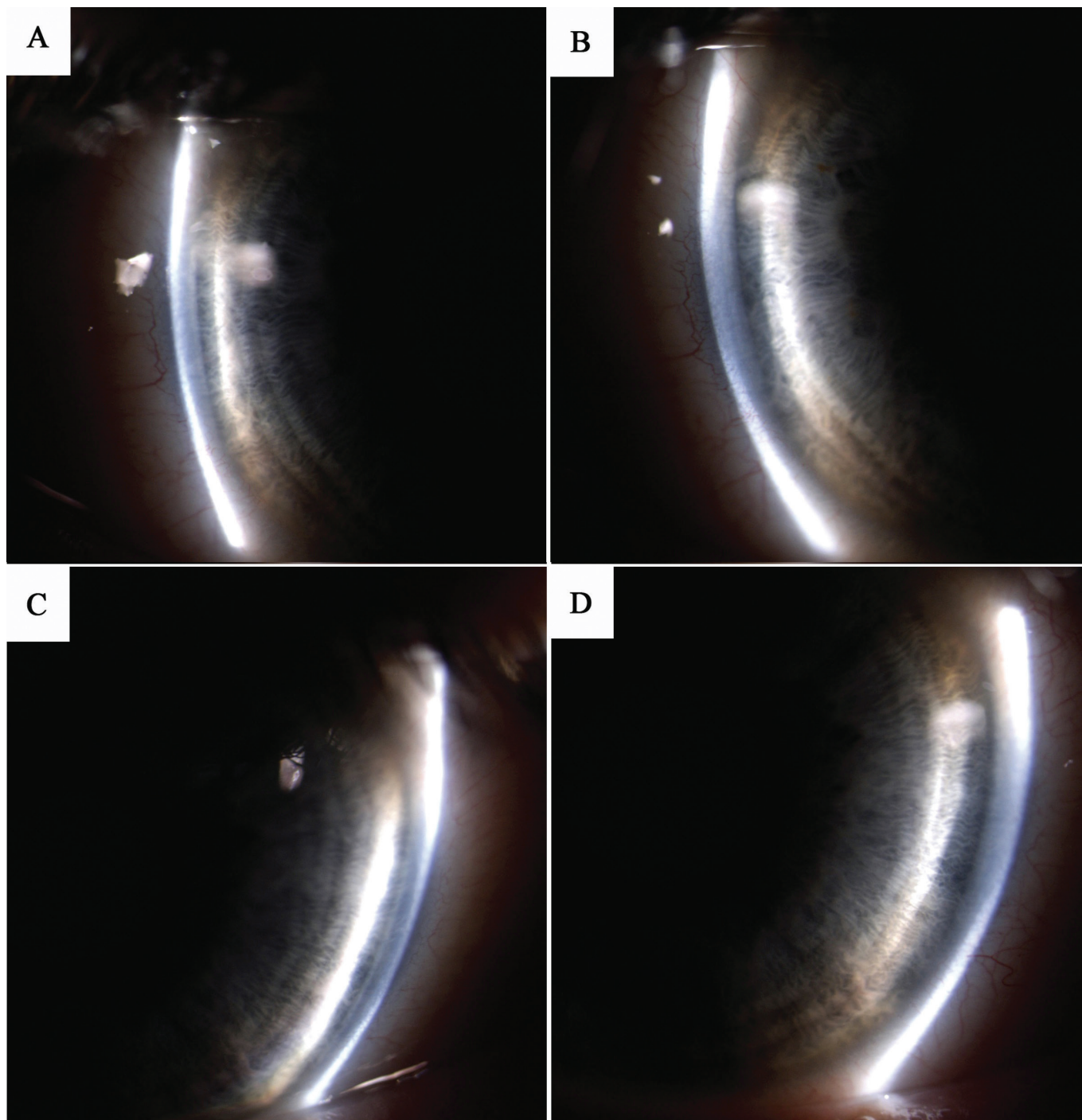


Fig. 1: Anterior segment photography – documentation of anterior chamber depth, A) right eye before discontinuation of trazodone, B) right eye after discontinuation of trazodone, C) left eye before discontinuation of trazodone, D) left eye after discontinuation of trazodone.

of the chamber angle was also recorded bilaterally (Fig. 2B and 2D). Intraocular pressure was normalised to values of 15 torr bilaterally. Subsequently the refractive status and parameters of the patient's anterior segments were stable. An overview of the refractometer and biometric results measured during the time of use and following discontinuation of trazodone is presented in table 1.

DISCUSSION

Acute induced myopia, which occurs in rare cases as an

adverse side effect of systemically administered medication, is most frequently described in the literature in the case of administration of sulfonamides (1): toprimate (3, 5, 10), acetazolamide (4), hydrochlorothiazide (14) and others. The mechanism of origin is explained by means of a swelling of the ciliary body, with a subsequent shift of the lens-iris diaphragm in a forward direction (7, 12). An association of acute myopia with the occurrence of supraciliary choroidal effusion with anterior rotation of the ciliary processes has also been described, confirmed by ultrasonic biomicroscopy (9, 13). The occurrence of

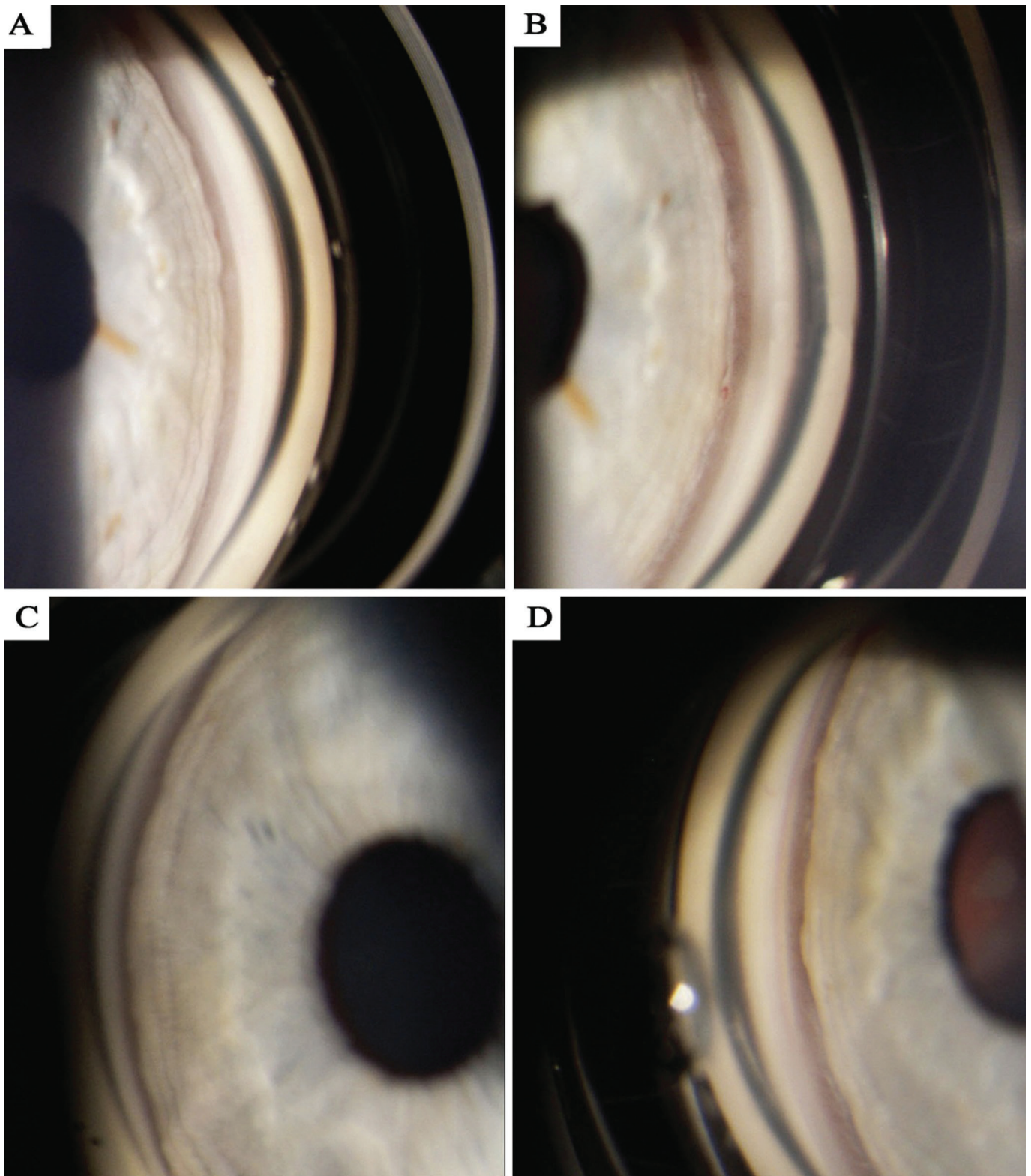


Fig. 2: Gonioscopy photograph – documentation of configuration of chamber angle, A) right eye before discontinuation of trazodone, B) right eye after discontinuation of trazodone, C) left eye before discontinuation of trazodone, D) left eye after discontinuation of trazodone.

acute angle-closure glaucoma has been stated as a further consequence of a shift of the lens-iris diaphragm (9, 13). In pathophysiology the mechanism of origin is considered to be potentially the effect of prostaglandins as substances causing vasodilation and an increase of vascular permea-

bility, which may lead to the onset of swelling of the ciliary body (8, 10).

In differential diagnosis it is necessary to exclude spasm of the ciliary muscle as a cause of acute myopia, by measurement of refraction in induced cycloplegia. The finding

Table 1: Changes of biometric results during use and after discontinuation of trazodone

	Right eye during use of trazodone	Right eye after discontinuation of trazodone	Left during use of trazodone	Right eye after discontinuation of trazodone
Spherical defect according to auto-refractometry [Ds]	-4,25	0,25	-5,50	0
Anterior chamber depth measured by biometry [mm]	2,97	3,32	2,84	3,36
Axial length of eyeball measured by biometry [mm]	24,07	24,07	24,02	24,02

in this case is not linked with shallowing of the anterior ocular chamber and constriction of the chamber angle. It is also necessary to consider hyperglycaemia induced by myopisation of the lens (6). A further factor in myopia may be the presence of a nuclear cataract (2).

In the case that induced myopisation due to medication leads to closure of the chamber angle, the performance of peripheral iridotomy is ineffective, since the closure is not caused by a primary pupillary block and an accumulation of chamber fluid in the region of the posterior chamber of the eye (9).

Trazodone is an antidepressant which belongs to the group of third generation monoamine reuptake inhibitors. It is a serotonin antagonist and reuptake inhibitor (SARI) with a dual mechanism. It is used most frequently for the treatment of depression, anxiety disorders and disorders of sleep or libido. Its adverse side effects include drowsiness, increased anxiety, dizziness, headaches, nausea, nocturnal hallucinations, reduced libido and others. In the available literature no publication has been found describing a correlation between the occurrence of acute induced myopia and the use of trazodone. However, an increased risk of the occurrence of acute angle-closure glaucoma has been described in predisposed eyes upon the use of anti-psychotic drugs and selective serotonin reuptake inhibitors (SSRI) (11). Trazodone not only inhibits reuptake of serotonin on the pre-synaptic membrane, but itself binds to certain serotonin receptors on the post-synaptic membrane. In this manner, unlike selective serotonin reuptake

inhibitors, it also has a dual effect of increasing the concentration of serotonin in the region of the synaptic cleft. It is therefore possible to expect that the use of trazodone may lead to similar adverse effects as in the case of the use of SSRIs in predisposed individuals.

In the diagnosis of acute myopia it is beneficial to use ultrasonic biomicroscopy (UBM) or anterior segment optical coherence tomography (OCT), which are capable of detecting any applicable supraciliary choroidal effusion with swelling of the ciliary body and sclera. Due to the unavailability of UBM or anterior segment OCT, in the presented case study it was not possible to document swelling of the ciliary body, as was the case for patients using trimethoprim (9) or topiramate (13). On the basis of the similarity of the clinical symptoms, it is possible to expect the presence of swelling of the ciliary body also in this case. In analogous cases it is possible to recommend UBM as a highly beneficial diagnostic method.

CONCLUSION

In the case of the occurrence of acute myopisation in a patient with an anamnesis of stable refraction, it is necessary to consider also an adverse side effect of systemic medication. This cause is rare, but relatively serious. Timely diagnosis and discontinuation of the therapy inducing undesirable myopisation may prevent the development of complications in the form of acute angle-closure glaucoma or supraciliary choroidal effusion.

LITERATURE

- Bovino, JA., Marcus, DF.:** The mechanism of transient myopia induced by sulfonamide therapy. *Am J Ophthalmol.*, 94 (1); 1982: 99-102.
- Brown, NA., Hill, AR.:** Cataract: the relation between myopia and cataract morphology. *B J Ophthalmol.*, 71(6); 1987: 405-414.
- Fraunfelder, FW., Fraunfelder, FT. et al.:** Topiramate-associated acute, bilateral, secondary angle-closure glaucoma. *Ophthalmology*, 111(1); 2001: 109-111.
- Garland, MA., Sholk, A. et al.:** Acetazolamide-induced myopia. *Am J Obst and Gyn*, 84(1); 1962: 69-71.
- Guier, CP.:** Elevated intraocular pressure and myopic shift linked to topiramate use. *Optom Vis Sci*, 84(12); 2007: 1070-1073.
- Gwinup, G., Villarreal, A.:** Relationship of serum glucose concentration to changes in refraction. *Diabetes*, 25(1); 1976: 29-31.
- Kaimbo, DKW.:** Transient drug-induced myopia. *SAJ Case Rep* [online] 1; 2014:105. [cit. 28. 3. 2018]. Dostupné na https://www.researchgate.net/profile/Dieudonne_Kaimbo_Wa_Kaimbo/publication/269930686_Transient_Drug-Induced_Myopia/links/54a457c50cf267bdb9067794.pdf
- Krieg, PH., Schippe, I.:** Drug-induced ciliary body oedema: A new theory. *Eye*, 10; 1996: 121-126.
- Postel, EA., Assalian, A., Epstein, DL.:** Drug-induced transient myopia and angle-closure glaucoma associated with supraciliary choroidal effusion. *Am J Ophthalmol.*, 122(1); 1996: 110-112.
- Rhee, DJ., Goldberg, MJ. et al.:** Bilateral angle-closure glaucoma and ciliary body swelling from topiramate. *Arch Ophthalmol.*, 119(11); 2001: 1721-1723.
- Richa, S., Yazbek, JC.:** Ocular adverse effects of common psychotropic agents: A review. *CNS Drugs*, 24(6); 2010: 501-526.
- Ryan, EH., Jampol, LM.:** Drug induced acute transient myopia with retinal folds. *Retina*, Fall/Winter,6(4); 1986: 220-223.
- Sankar, PS., Pasquale, LR., Grosskreutz,**

CL.: Uveal effusion and secondary angle-closure glaucoma associated with topiramate use. Arch Ophthalmol., 119(8);

2010: 1210-1211.

14. **Young-Rae, R., Woo, SJ. et al.:** Acute-onset bilateral myopia and ciliocho-

roidal effusion induced by hydrochlorothiazide. Kor J Ophthalmol., 25(3); 2011: 214-217.