

ACUTE KERATOUEITIS WITH CORNEAL GRAFT MELTING AS A LATE COMPLICATION OF MILD CHEMICAL BURN POTENTIALLY ASSOCIATED WITH COVID-19 INFECTION: A CASE REPORT

Majtánová N.^{1,2}, Kurilová V.¹, Krišková P.¹, Kéri P.¹, Fellner Z.¹, Cholevík D.¹, Majtán J.^{3,4}, Kolář P.^{1,2}

¹Department of Ophthalmology of Slovak Medical University and University Hospital, Bratislava, Slovakia

²Faculty of Medicine, Slovak Medical University, Bratislava, Slovakia

³Institute of Molecular Biology, Slovak Academy of Science, Bratislava, Slovakia

⁴Department of Microbiology, Faculty of Medicine, Slovak Medical University, Bratislava, Slovakia

The authors of the work declare that the creation and topic of the manuscript and its publication are not in conflict of interest and are not supported by any pharmaceutical company. The work has not been submitted to another journal or published elsewhere, except for congress abstracts and recommended procedures.

Received: December 30, 2022

Accepted: May 19, 2023

Available on-line: July 30, 2023



MUDr. Nora Majtánová, Ph.D.

Očná klinika SZU a UNB

Antolská 11

851 07 Bratislava

E-mail: nora.majtanova@gmail.com

SUMMARY

Chemical burns are sight-threatening injuries that require immediate management. The main goal of the initial treatment is prompt and copious irrigation to neutralize and eliminate the chemical, followed by various therapeutic options (conservative and surgical) according to the individual patient's postinjury findings.

Purpose: In this case report, we describe the course and treatment of a patient with chemical alkali burns of both eyes.

This study reports the outcomes of an ocular alkali burn patient who became infected with COVID-19 and where severe keratouveitis with corneal graft melting and hypopyon occurred, ultimately resulting in evisceration of the eye.

Observations: We report the case of a 35-year-old woman, after an alkali burn of both eyes. Complete re-epithelialization of both corneas occurred within three weeks. Due to this observation, we assumed a satisfactory healing prognosis. However, corneal lysis occurred in the left eye over time. The condition was managed, but subsequently severe keratouveitis with hypopyon and corneal lysis occurred in the left eye, apparently in connection with the COVID-19 infection, which ultimately led to the evisceration of the affected eye.

Conclusions and Importance: In the case report, we describe the management of a mild chemical alkali burn of the right eye and a complicated moderate burn of the left eye with an alkaline chemical. Both eyes were completely healed within three weeks. However, the findings on the left eye became complicated, which ultimately led to the evisceration of the affected eye. The disease of COVID-19 could have contributed to the deterioration of the findings on the cornea, or it could have just been a coincidence of two diseases, with the keratouveitis having a serious course due to the previous difficult course of healing and many complications after the chemical burn.

Key words: chemical burn; amniotic membrane; corneal re-epithelialization; corneal melting; perforation keratoplasty; COVID-19

Čes. a slov. Oftal., 79, 2023, No. 4, p. 192–200

INTRODUCTION

Chemical ocular trauma is an emergency condition, requiring a rapid diagnosis and immediate medical treatment to minimize severe complications and profound visual loss. The severity of chemical burn injury depends on several factors, such as the type of chemicals and their pH value, temperature, volume, concentration, as well as the time of exposure [1]. Alkali agents, due to their lipo-

philicity, cause liquefaction necrosis with deeper tissue penetration and irreversible changes. In contrast, acid agents can cause injury due to coagulation-type necrosis, which tends to self-limit further damage [2].

After a chemical burn of the cornea, direct tissue damage could result in corneal ulceration, accompanied by an undesired destructive inflammatory immune response arising from the corneal surface and the tear film. Therefore, the major aims of severe acute ocular chemical

burn treatment are to decrease inflammation, accelerate epithelial healing, avoid further epithelial and stromal breakdown, and prevent cicatricial complications.

Several options for the treatment of ocular chemical burns are available, including anti-inflammatory therapy using corticosteroids, prevention of stromal breakdown using tetracyclines, promotion of re-epithelialization using amniotic membrane transplantation and contact lens bandage [3]. For this purpose, silicone-hydrogel contact lenses are used [4], which reduce pain and accelerate the healing of the eye surface [5,6]. When using the amniotic membrane, it is also advisable to cover it with a contact lens, which will prevent its premature detachment and promote complete epithelialization of the cornea [7].

There are two well-known and most-used chemical burn classification systems, namely Roper-Hall and Dua's classifications [1]. The Roper-Hall classification system is based on grading the injury by the extent of corneal haze and perilimbal ischemia. Dua's classification is based on the percentage of bulbar conjunctival involvement and clock-hour limbal involvement, which provides better management strategies and prognosis evaluation [8]. Serious cases might result in corneal thinning, ulcers, scleral melting, and risk of perforation. Late complications include symblepharon formation, entropion, ectropion, glaucoma, severe dry eye disease, and corneal scarring with neovascularization [9]. To prevent symblepharon formation, a symblepharon ring could be used [10].

Ocular manifestations of COVID-19 infection, in general, were reported in 4.3% of patients, in 0.9% as the first or only symptom. The most common, and sometimes first symptom is conjunctival congestion, followed by chemosis, foreign body sensation, epiphora, dry eye, and blurred vision [11]. Keratoconjunctivitis with pseudodendritic, subepithelial, and epithelial small infiltrates as the main COVID-19 symptom, was presented in a patient with mild respiratory symptoms, excluding fever [12]. COVID-19 infection could also have a negative impact on other ongoing ocular conditions, especially after keratoplasty. Rejection of keratoplasty grafts was described following

COVID-19 infection in [13–15]. Similarly, rejection was also mentioned after COVID-19 vaccination [16–19].

In our case report, we present a patient with chemical alkali burn of both eyes, the course of her conservative and surgical treatment with numerous complications, including a COVID-19 infection, ultimately leading to the development of keratouveitis with corneal melting requiring evisceration of the left eye.

CASE REPORT

On January 30, 2021, a 35-year-old female patient came to the emergency service of the Eye Clinic of SZU and UNB with burning, redness, and pain in both eyes. Difficulties arose immediately after the accident – Sifo siphon cleaner containing granules of 100% sodium hydroxide (ES 215-185-5) was accidentally injected into both eyes, which was mixed with hot water, forming an exothermic reaction. The marking of the composition of the chemical and recommendations for protection when working with it on the packaging of the Sifo product were insufficient – the warning was only indicated on the packaging in small print on the sides. The patient repeatedly rinsed her eyes with tap water at home after the injury. However, as she continued to feel severe pain, she sought an eye examination at a regional hospital the next day (after 24 hours). The patient was ophthalmoscopically examined, the conjunctival sac was repeatedly rinsed with saline solution, and topical fluoroquinolone antibiotics and epithelialization gel were administered. She was immediately sent to our hospital with the findings of conjunctival and corneal burns of both eyes, as well as with the suspicion of ischemia of the corneal limbus on the left.

The patient arrived in our Department 48 hours after the injury, and we admitted her to the hospital. According to her general medical history, the patient was treated for allergies and bronchial asthma, she has no other general illnesses. For allergies, she takes cetirizine tablets 10 mg once daily; for asthma, fluticasone inhaler 125 µg 2 injections twice daily and ipratropium bromide

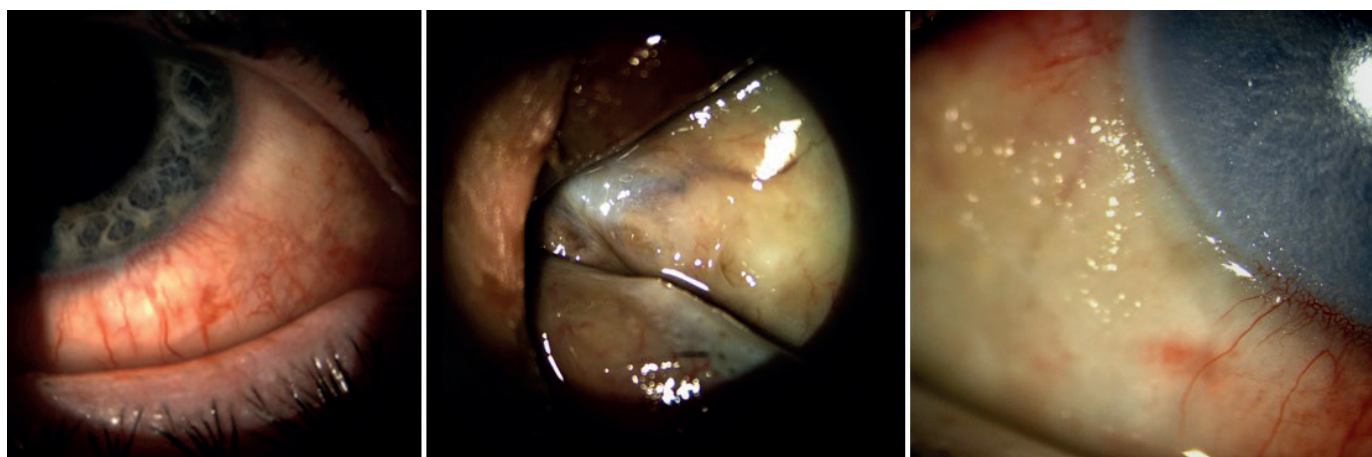


Figure 1. Initial findings of the left eye after chemical burn. Chemical burn of the conjunctiva and limbus, brownish appearance of necrotic conjunctiva altogether with the caruncula of the left eye and a corneal epithelial defect with limbal ischaemia of the left eye (from left to right)

inhaler as needed, on average twice daily, and a montelukast tablet once daily.

At the time of arrival at our workplace, visual acuity was 20/32 and 20/40 in the right and left eye, respectively. On

the ophthalmoscopic examination of the right eye, conjunctival hyperemia and chemosis, and a wedge-shaped defect of the cornea with reduced corneal transparency were present. The limbus area of the right eye was not

Table 1. Initial chemical alkali burns patient's treatment regimen during hospital stay from 30.1.2021 to 8. 2. 2021

Topical treatment		
	eye	
	right	left
levofloxacin 0.5% gtt.	5x times a day	every hour 5 days, then 5 times a day
homatropine 4% gtt.	t.i.d.	t.i.d.
artificial non- preservative tears gtt.	10 times a day	10 times a day
dexamethasone 0.1% gtt.	-	5 times a day from 5th day
Parenteral treatment		
cefotaxime	1 g b.i.d. i.v. 10 days	
methylprednisolone	1 g daily i.v. 4 days, 500 mg 1 day and 250 mg 5 days	
ascorbic acid	500 mg daily i.v. 10 days	

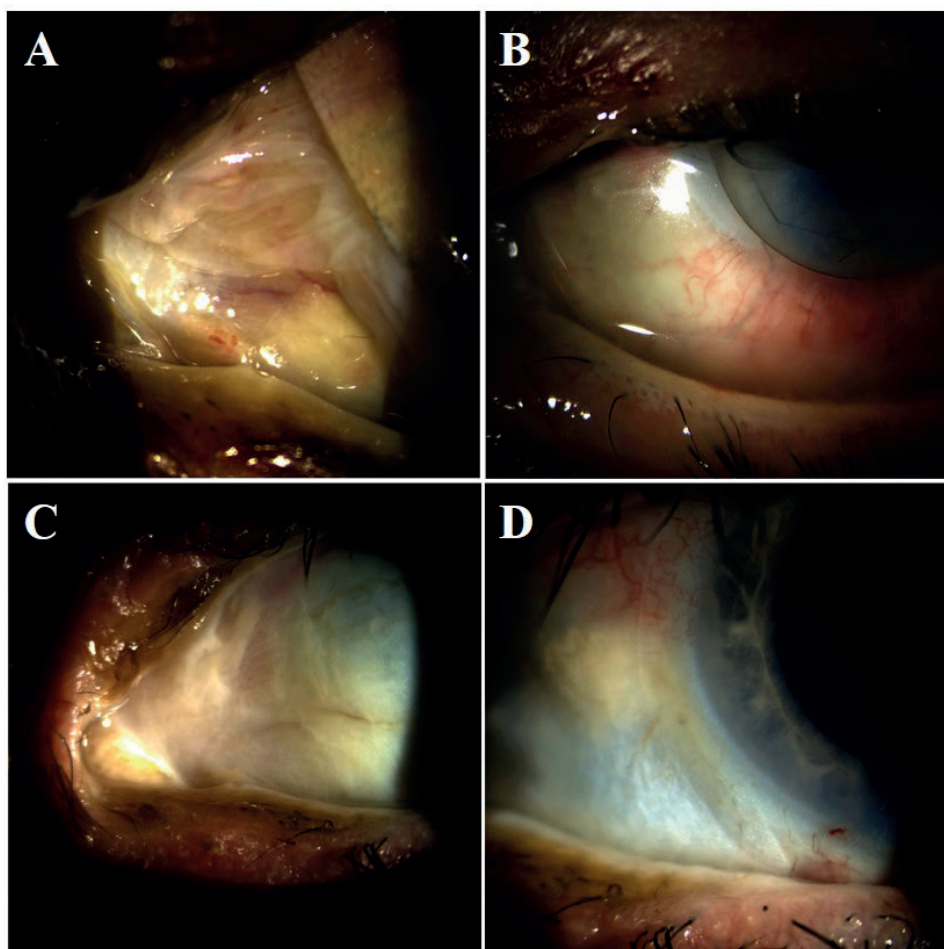


Figure 2. Healing of the conjunctiva and cornea with amniotic membrane and symblepharon ring. Amniotic membrane with symblepharon ring (A, B), healed conjunctiva and cornea after one month of soft contact lens-enhanced reepithelialization after symblepharon ring removal (C, D)

damaged. On the left eye, the caruncle and the nasal part of the lower eyelid margin showed signs of necrosis, with a dark red to brownish coloration. The nasal part of the bulbar conjunctiva was also necrotic. The limbus of the cornea of the left eye was also affected, with ischemia in the range of three digits. Moreover, an extensive epithelial defect of the cornea was present (Figure 1).

Based on the classification of Ocular Surface Burns according to Dua, we classified the findings on the right eye into the I. degree of damage and the findings on the left eye into the III. degree of damage. We continued to rinse both eyes of the patient with 3 % boric acid. The initial medical management of chemical burns in both eyes is shown in Table 1.

On the fourth day after the injury, due to insufficient re-epithelialization of the surface of the left eye, it was necessary to cover the surface of the eye (both the corneal and the nasal part of the bulbar conjunctiva) with an amniotic membrane. At the same time, a symblepharon ring, to prevent the formation of symblepharons, was implanted (Figure 2) Ascorbic acid (vitamin C) was administered intravenously to promote re-epithelialization. Topical antibiotic treatment of the left eye was reduced to 5 drops per day, and topical corticosteroid treatment with 0.1 % dexamethasone at a dose of 5 drops per day was added to the treatment.

We released the patient to outpatient care on February 8, 2021. Intravenous treatment was stopped on the day of discharge and replaced by oral therapy (cefuroxime and methylprednisolone tablets), and topical treatment continued (Table 2).

On February 12, 2021, at the first outpatient examination after hospitalization, absorption of the amniotic membrane occurred. The symblepharon ring was removed and a soft contact lens was fitted to cover the corneal surface for the next 10 days to reduce pain and promote the corneal re-epithelialization process. (Figure 2). The conjunctiva and cornea were almost completely re-epithelialized, and the ischemia of the limbus in a range of 6 to 9 hours persisted. At number 9, there was still a small defect of the corneal epithelium, with a surrounding necrotic lesion of the conjunctiva and corneal nubecule. Central visual acuity (CVA) was 20/20 without correction. We also investigated preserved corneal esthesia with a manual Cochet-Bonnet esthesiometer. We continued to treat the left eye with topical levofloxacin, dexamethasone, homatropine, and lubricants (Table 2).

The next follow-up examination of the patient was in 4 days, with the replacement of the contact lens, and the next one in 6 days, when the cornea was already completely re-epithelialized, followed by stopping the topical homatropine treatment and scheduling the next follow-up in 3.5 weeks.

At this time, the findings on the cornea of the right eye were completely healed; the cornea was smooth, shiny, and clear, and the conjunctiva was healed with no redness. The incipient entropion and mild trichiasis were no-

ticed on the upper eyelid, and CVA of the right eye was 20/20 without correction.

At the follow-up examination after 3.5 weeks, in March 2021, there was a drop in the uncorrected CVA in the left eye to 20/32. To achieve CVA 20/20, a myopic correction of -0.75 spherical diopter was necessary, as there was a change in the refractive power of the cornea, which was also confirmed by corneal topography. Corneal topography also showed thinning of the left cornea in the lower nasal quadrant; the front surface of the cornea was without steepening, the stroma was thinned to 321 μm , while the center was 494 μm . Considering the integrity of the cornea, surgical intervention in the sense of eccentric keratoplasty was not indicated. We did not change the treatment, we continued with the treatment, the patient was already treated with topical antibiotics, corticosteroids, and lubricants.

We scheduled her to be examined with corneal topography in 1 month. However, we did not have time to perform the topography, as the patient presented acutely earlier, which will be described further in the text.

On April 16, 2021, the patient came in for an acute examination, due to pain in the left eye, with a significant decrease in visual acuity, to the level of the number of fingers in front of the eye. The patient had scleromalacia and corneomalacia in the lower nasal quadrant, which led to corneal perforation, atalamia, and incarceration of the iris into the corneal perforation wound. (Figure 3A) We admitted the patient to the hospital. Surgical treatment consisted of the removal of the necrotic part of the iris, mainly at 8 hours, eccentric perforation keratoplasty, and scleroplasty in the nasal lower quadrant (Figure 3B). The surgical procedure was performed under antibiotic coverage (cefotaxime was administered intravenously). After the surgery, the patient was also given cyclosporin A as an immunosuppressive therapy, to reduce the risk of transplant rejection.

We released her to outpatient care on April 30, 2021. The patient attended regular follow-up examinations, and the findings were stabilized.

On June 29, 2021, one corneal suture was loosened and purulent endophthalmitis developed. The patient underwent urgent 25G pars plana vitrectomy, with vitreous removal, followed by silicone oil tamponade, together with vitreous sample culture testing. At the same time, irrigation of the anterior chamber of the eye and application of intracameral and intravitreal cefuroxime antibiotics were performed. Two pathogens – *Staphylococcus* sp. and *Streptococcus pneumoniae* – were determined by culture testing, both sensitive to ofloxacin.

In July 2021, it was again necessary to apply the amniotic membrane to the surface of the eye, due to the progressive thinning of the maternal cornea. Parabulbar dexamethasone, oral cefuroxime, topical levofloxacin, and loteprednol were administered. We continued systemic cyclosporin therapy. In the following 2 months, the patient's findings were transiently stable, she came for follow-ups every 2 weeks.

Table 2. Best corrected visual acuity, ocular complications and treatment of the patient's left eye after chemical alkali burn sorted by time periods

Time period	Best corrected visual acuity	Ocular complication	Surgical or other treatment	Pharmacological treatment
2/2021 (from hospital discharge)	20/20		contact lens putting on and changing	levofloxacin 0.5% gtt. 5 times a day dexamethasone 0.1% gtt. 5 times a day homatropin 4% gtt. t.i.d. artificial tears gtt. 10 times a day dexpantenol gel oph 5 times a day cefuroxim 500 mg tbl p.o. b.i.d. 10 days methylprednisolone 16 mg tbl p.o. q.d. then tapering 4 mg per week
3/2021	20/20	refraction change		levofloxacin 0.5% gtt. 5 times a day dexamethasone 0.1% gtt. 5 times a day artificial tears gtt. 10 times a day dexpantenol gel oph 5 times a day methylprednisolone 4 mg tbl p.o. q.d.
4/2021	counting fingers	corneal perforation, scleromalation	eccentric perforation keratoplasty, scleral graft patching, basal iridectomy	levofloxacin 0.5% gtt. 5 times a day dexamethasone 0.1% gtt. 5 times a day artificial tears gtt. 5 times a day cefotaxime 1g i.v. b.i.d. 15 days cyclosporine 150 mg tbl p.o. b.i.d.
6/2021	counting fingers	endofthalmitis	25G pars plana vitrectomy, silicon oil tamponade	levofloxacin 0.5% gtt. 5 times a day tobramycin 0.3% gtt. 5 times a day homatropin 4% gtt. t.i.d. loteprednol 0.5% gtt. artificial tears gtt. 5 times a day dexamethasone p.b. cefotaxime 1g i.v. b.i.d. 25 days gentamycin 240 mg 1 times a day i.v. 25 days cefuroxim ivt. cyclosporine 150 mg tbl p.o. b.i.d.
7/2021	20/200	maternal corneal thinning	amniotic membrane	levofloxacin 0,5% gtt. 5 times a day artificial tears gtt. cyclosporine 150 mg p.o. 2 times a day
9/2021	20/200	scleral patch graft dehiscence	scleral patch graft revision	levofloxacin 0.5% gtt. 5 times a day dexamethasone 0.1% gtt. 5 times a day artificial tears gtt. cyclosporine 150 mg p.o. b.i.d.
10/2021	20/100	intraocular pressure rise		dorzolamid+timolol gtt. b.i.d. dexamethasone 0.1% gtt. 5 times a day artificial tears gtt. 5 times a day cyclosporine 150 mg tbl p.o. b.i.d.
11/2021	20/60		removal of some single corneal graft patch stitches	dorzolamid+timolol gtt. b.i.d. dexamethasone 0.1% gtt. 5 times a day artificial tears gtt. 5 times a day cyclosporine 150 mg tbl p.o. b.i.d.
12/2021	counting fingers from 1 m	keratouveitis and corneal melting with hypopyon	evisceration of the eye	levofloxacin 0.5% gtt. 5 times a day dexamethasone 0.1% gtt. 5 times a day dorzolamid+timolol gtt. b.i.d. cefotaxime 1g i.v. b.i.d. 7 days gentamycin 240 mg q.d. i.v. 7 days alfa aescin tbl p.o. 2 tbl t.i.d.

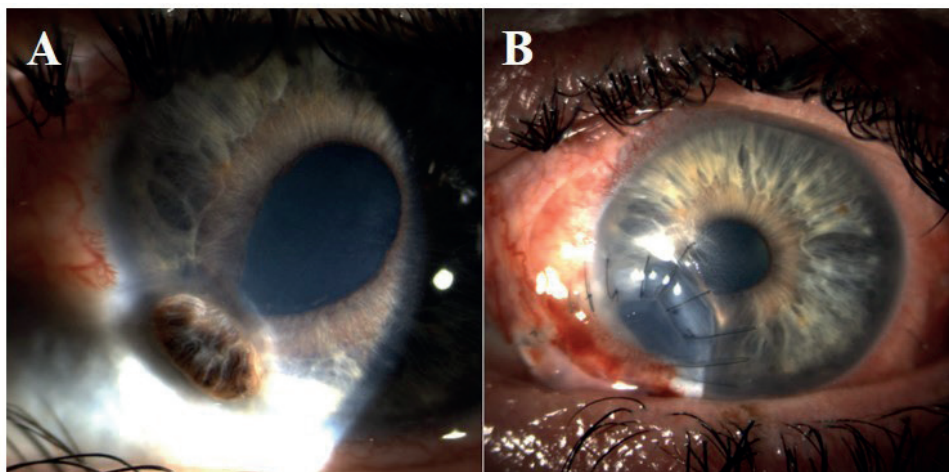


Figure 3. Corneal perforation, iris incarceration and atalasia altogether with nasal scleromalacia (A). Subsequent surgery consisted of excentric perforation keratoplasty, nasal scleral graft and artificial iris coloboma at 8 o'clock (B)

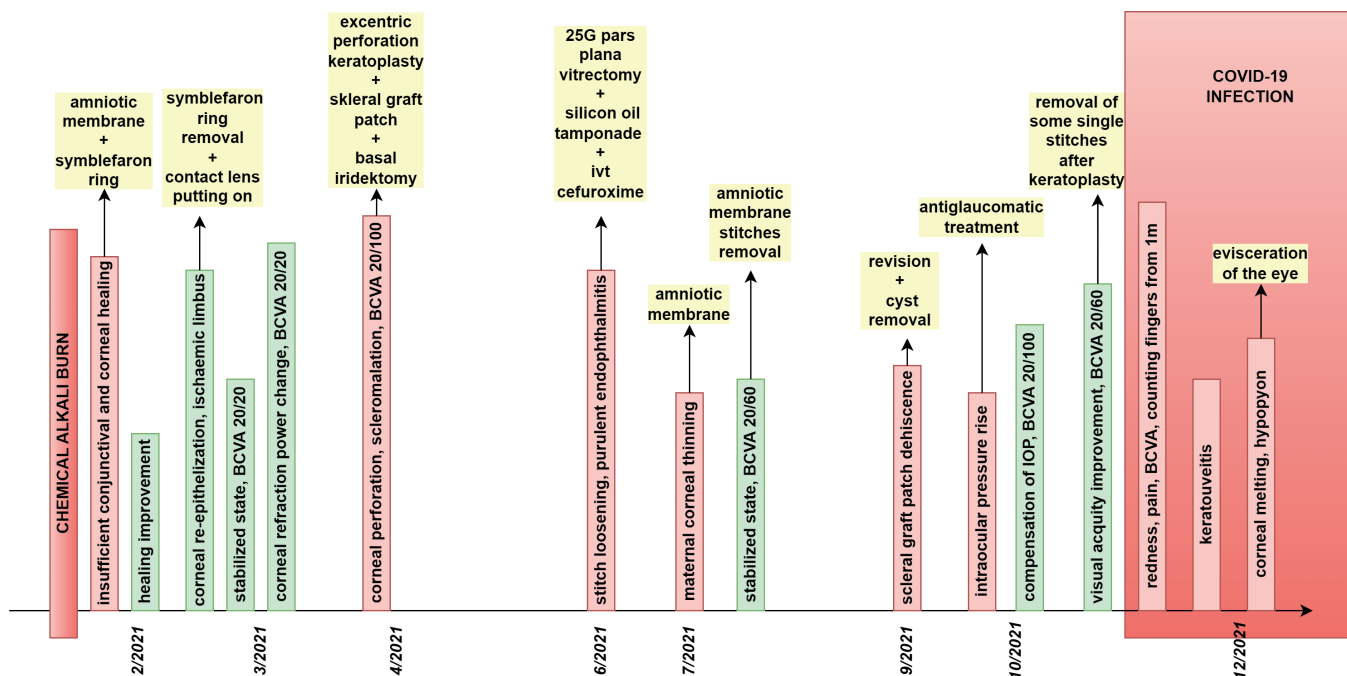


Figure 4. Scheme of the patient's left eye findings and their management over time
BCVA – Best corrected visual acuity, ivt – intravitreal

At the end of September 2021, the patient had to undergo another operation, due to a finding of scleral graft dehiscence that was suddenly detected during the examination. During the revision, a cyst was found between the thinned maternal sclera and the scleral graft. Two weeks after the surgery, there was an elevation of the intraocular pressure in the operated eye, with the necessity of prescribing a combination of two antiglaucomatic medications, leading to compensated intraocular pressure.

In the following 2 months, the best-corrected visual acuity of the left eye improved. In October 2021, it was 20/100, and, in November 2021, some single stitches of the graft were removed with subsequent central

visual acuity of 20/60. The local findings were stable – the edges of the transplant were sealed, and there were nuchal opacities around the sutures. Otherwise, the transplant was transparent.

In December 2021, the patient informed us that she was infected with COVID-19. She tested positive using a PCR test (CT value 14) and mutation analysis revealed the Delta variant of the coronavirus. The patient subjectively complained of redness and pain in the left eye. Clinically, however, apart from the conjunctival injection, there was no worsening of the local findings of the left eye. We therefore assumed the presence of an acute viral infection with bacterial superinfection, in connection with the

ongoing COVID-19 disease. The patient was hospitalized to monitor the clinical course of the disease. We detected hypoesthesia of the cornea, which was verified using a hand-held esthesiometer (Cochet-Bonnet). From the beginning of hospitalization, systemic intravenous and topical antibiotic therapy was administered.

On Day 5 of hospitalization, despite therapy, the patient developed acute keratouveitis of the corneal transplant, with hypopyon in the anterior chamber. A smear from the conjunctival sac and the cornea revealed the presence of *Pseudomonas aeruginosa*. The course of the infection was very rapid, including significant infiltration of the corneal graft, with critical corneal center thinning. The patient subjectively complained of unbearable pain in the eye. We decided to proceed to the evisceration of the patient's left eye, with the object of overcoming complicated left ocular healing and ongoing infection of COVID-19. The convalescence was uncomplicated, and the course of the COVID-19 infection was mild.

The overall course of the treatment and clinical findings of the patient are chronologically summarized in Figure 4. Complications of the left eye after the initial healing of the ocular surface and surgical and medical treatment are shown in Table 2.

The course of the patient's COVID-19 disease was mild, the treatment was symptomatic. The patient was not given any antiviral drugs or monoclonal antibodies. During the infection, the patient's bronchial asthma worsened, with the need to increase the doses of long-term medications – fluticasone inhaler with an increase in the dose to 250 µg 2 inhales twice daily and ipratropium bromide on average 5 times per day. In addition, the patient was under significant stress, because her mother had died of a COVID-19 infection at that time.

DISCUSSION

Current treatment of mild to moderate chemical eye burns is sufficient to stabilize the eye surface and visual acuity. On the other hand, its success rate is reduced for severe chemical burns. In recent years, the overall incidence of chemical eye burns has increased [20]. Similarly, there is evidence suggesting an increase in the incidence of severe ocular chemical burns [21]. Injuries with alkaline substances lead to more severe tissue damage with a worse prognosis, compared to acids. It is reported that approximately two-thirds of chemical eye burns in patients are of alkaline origin. This is caused by the common use of cleaning and disinfecting agents based on ammonia and sodium hydroxide [22]. After examining the circumstances of the accident from our case report, in our opinion, we came across insufficient labeling and warnings related to the safety instructions of the chemical product that caused the accident. The mentioned product had a warning only on the sides of the packaging, written in very small print size. Manufacturers of toxic products or irritating substances are encouraged to display warnings in large print sizes in a visible location

for their customers. If the manufacturer does not do so, patients do not realize that they are working with such a dangerous chemical, resulting in not using any protective equipment such as gloves or protective glasses, which can lead to serious consequences, as in our case report.

In this case report, the early treatment and subsequent therapeutic procedures of a patient after a chemical alkali burn during the COVID-19 pandemic was presented. Immediate irrigation of the eye immediately after the chemical burn, which the patient performed herself at home, even if only with tap water, was essential, as it helped to shorten the exposure time, neutralize the pH and thereby reduce the consequences of the damage [23]. On the other hand, the patient did not seek the help of a doctor immediately, but only after 24 hours, and she also attended our Department one day late, having been sent from the regional hospital.

Knowledge of chemical properties is essential for proper patient management. After achieving a neutral pH by irrigation, clinical evaluation and classification follow [24]. In our case, we knew the type of the chemical, so we proceeded to immediate and repeated rinsing with 3% boric acid in the attempt to neutralize it. We assumed that timely irrigation and neutralization of the chemical, with subsequent intensive medical treatment significantly contributed to the complete healing of the less burned right eye.

However, patients with severe chemical eye burns require a more complex approach, often requiring some surgical procedures. One of the options for the treatment of the acute and early reparative phase is the transplantation of the amniotic membrane. The membrane expresses growth factors that help to stimulate epithelial growth, reduce inflammation, and prevent symblepharon formation [25]. It can better prepare a patient who is indicated for perforating keratoplasty or stem cell transplantation [26]. According to Dua's classification, amniotic membrane transplantation should be performed in patients with Grade III and IV chemical burns. However, other studies have shown that amniotic membrane transplantation is also suitable for patients with II. degree of a chemical burn, mainly due to its ability to promote corneal re-epithelialization [27]. Unequivocal criteria for amniotic membrane transplantation have not been established [28] and its effectiveness needs to be established [29]. In the presented case report, the patient was classified as I. grade on the right eye and III. grade on the left eye, according to Dua's classification.

We applied the amniotic membrane to the patient twice: the first time immediately during the initial hospitalization, and the second time during the complication of further thinning of the maternal cornea in the further course of the disease. The amniotic membrane was covered with a contact lens to promote epithelialization and to prevent premature detachment of the membrane [7]. Ascorbic acid (vitamin C) was also administered intravenously to support re-epithelialization, thus supporting reparative processes through the for-

mation of collagen [8] and making healing of the cornea under the contact lens more effective.

The literature further describes the use of oral and topical tetracyclines in severe chemical burns, due to their inhibition of collagen degradation in the cornea [31]. Due to the lack of experience with tetracycline therapy for chemical eye burns at our workplace, we did not use them, but we plan to include them in the treatment in future similar cases.

In the course of further healing, the patient experienced a sudden change in refraction, which we confirmed with corneal topography, along with thinning of the cornea. A change in refraction could be a possible precursor of a subsequent complication in terms of the corneal stromal melting with its perforation in the nasal lower quadrant. We can assume that it was an incipient melting of the corneal stroma as a result of the primary chemical burn. At that time, due to the integrity of the cornea, surgical intervention in the sense of eccentric keratoplasty was not indicated. However, further progress indicates that we should have decided to examine the patient together with follow-up corneal topography in a shorter period.

In the case of the development of other chronic complications, limbal cell transplantation, lamellar and perforating keratoplasty, or keratoprosthesis (in the terminal stage of corneal disease) are usually indicated. Eccentric perforation keratoplasty and scleral patching were performed on our patient. The condition was complicated by endophthalmitis, which was surgically treated by pars plana vitrectomy with silicone oil tamponade, which exhibits antimicrobial activity for an inhibitory effect on various pathogens [32].

The long-term unfavorable and complicated course of healing of the left eye was finally stabilized 2 months after the secondary glaucoma was treated. The deterioration after this period occurred together with the infection of COVID-19 during the pandemic. In a period with a higher incidence of COVID-19 infections, a reduced frequency of patient examinations, whether by the doctor, the patient, or the medical facility, can have a negative impact on the patient's findings [33][34]. In our case, this impact was negligible. Apart from the initial delay after the injury, the patient came for follow-up examinations on time at pre-agreed intervals, and our Clinic was operative with minimal restrictions at that time.

The disease of COVID-19 can also have symptoms affecting the eyes. In the literature, keratoconjunctivitis is

described as a possible manifestation [12], and several works document the rejection of transplanted grafts after infection or vaccination against this disease [13-19]. Ocular surface neuropathy induced by Sars-CoV-2 infection was recently described [30]. The authors of this study suggest that the morphological changes found in the corneas of patients with COVID-19 are similar to those found in diabetic corneas and are accompanied by functional loss and changes in sensitivity. In addition, the infection of COVID-19 harms the corneal endothelium, with a reduction of endothelial and hexagonal cells [35]. In this case report, corneal hypoaesthesia was examined with a hand-held esthesiometer (Cochet-Bonnet) after the diagnosis of COVID-19. These findings indicate that the infection of COVID-19 could have harmed corneal functions and promoted the development of a secondary bacterial superinfection, which led to severe keratouveitis with corneal melting, requiring evisceration of the left eye after a previous complicated course of chemical eye injury.

CONCLUSION

We presented the case report of a patient after a chemical alkali burn of a mild degree on the right eye (Grade I of Dua's classification) and of a moderate degree on the left eye (Grade III of Dua's classification). Both eyes were completely healed after 3 weeks of treatment, but subsequently, the findings on the left eye became complicated. After complicated healing of the left eye, the patient became infected with a COVID-19 virus, followed by the development of acute keratouveitis with corneal graft melting with the formation of a hypopyon, which ultimately led to the evisceration of the eye. In the course of the described disease, we noticed numerous complications in the patient, which were resolved, and the findings subsequently stabilized. The final worsening of the local findings of the patient's left eye during the peak of the disease of COVID-19 indicates the influence of infection with the SARS-CoV-2 virus. The severe course of keratouveitis may be associated with a decrease in immunity, or with the disruption of the surface barrier of the eye during the infection of COVID-19, which could have facilitated the transfer of pathogens to the corneal transplant. At the same time, however, it is possible that it could only be a coincidence of two diseases, and the keratouveitis had a serious course due to the previous difficult healing and many complications after the chemical burn of the eye.

REFERENCES

1. Baradaran-Rafii A, Eslani M, Haq Z, Shirzadeh E, Huard MJ, Djalian AR. Current and upcoming therapies for ocular surface chemical injuries. *Ocul Surf.* 2017 Jan;15(1):48-64.
2. Wagoner MD. Chemical injuries of the eye: current concepts in pathophysiology and therapy. *Surv Ophthalmol.* 1997 Jan-Feb;41(4):275-313.
3. Bizrah M, Yusuf A, Ahmad S. An update on chemical eye burns. *Eye.* 2019 Sep;33(9):1362-1377.
4. Ambroziak AM, Szaflik JP, Szaflik J. Therapeutic use of a silicone hydrogel contact lens in selected clinical cases. *Eye Contact Lens.* 2004 Jan;30(1):63-67.
5. Lim-Bon-Siong R, Valluri S, Gordon ME, Pepose JS. Efficacy and safety of the ProTek (Vifilcon A) therapeutic soft contact lens after photorefractive keratectomy. *Am J Ophthalmol.* 1998 Feb;125(2):169-176.
6. Lim L, Lim EWL. Therapeutic contact lenses in the treatment of corneal and ocular surface diseases - a review. *Asia-Pac J Ophthalmol.*

- 2020 Dec;9(6):524-532.
7. Gris O, del Campo Z, Wolley-Dod C, et al. Amniotic membrane implantation as a therapeutic contact lens for the treatment of epithelial disorders. *Cornea*. 2002 Jan;21(1):22-27.
 8. Singh P, Tyagi M, Kumar Y, Gupta KK, Sharma PD. Ocular chemical injuries and their management. *Oman J Ophthalmol*. 2013 May;6(2):83-86.
 9. Soleimani M, Naderan M. Management strategies of ocular chemical burns: current perspectives. *Clin Ophthalmol*. 2020 Sep 15;14:2687-2699.
 10. Eslani M, Baradaran-Rafii A, Movahedan A, Djalilian AR. The ocular surface chemical burns. *Journal of Ophthalmology*. 2014;2014:196827.
 11. Ho D, Low R, Tong L, Gupta V, Veeraraghavan A, Agrawal R. COVID-19 and the ocular surface: a review of transmission and manifestations. *Ocul Immunol Inflamm*. 2020 Jul 3;28(5):726-734.
 12. Cheema M, Aghazadeh H, Nazarali S, et al. Keratoconjunctivitis as the initial medical presentation of the novel coronavirus disease 2019 (COVID-19). *Can J Ophthalmol*. 2020 Aug;55(4):e125-e129.
 13. Bitton K, Dubois M, Courtin R, Panthier C, Gatinel D. Descemet's membrane endothelial keratoplasty (DMEK) rejection following COVID-19 infection: A case report. *Am J Ophthalmol Case Rep*. 2021 Sep;23:101138.
 14. Jin SX, Juthani VV. Acute corneal endothelial graft rejection with coinciding COVID-19 Infection. *Cornea*. 2021 Jan;40(1):123-124.
 15. Moriyama AS, Campos MSQ. Presumed DMEK graft rejection associated with COVID-19 Infection. *Cornea*. 2022 Feb 1;41(2):e1.
 16. Wasser LM, Roditi E, Zadok D, Berkowitz L, Weill Y. Keratoplasty rejection after the BNT162b2 messenger RNA vaccine. *Cornea*. 2021 Aug 1;40(8):1070-1072.
 17. Shah AP, Dzhaber D, Kenyon KR, Riaz KM, Ouano DP, Koo EH. Acute corneal transplant rejection after COVID-19 vaccination. *Cornea*. 2022 Jan 1;41(1):121-124.
 18. Rajagopal R, Priyanka TM. Stromal rejection in penetrating keratoplasty following COVID-19 vector vaccine (Covishield) – A case report and review of literature. *Indian J Ophthalmol*. 2022 Jan;70(1):319-321.
 19. Yu S, Ritterband DC, Mehta I. Acute corneal transplant rejection after severe acute respiratory syndrome coronavirus 2 mRNA-1273 vaccination. *Cornea*. 2022 Feb 1;41(2):257-259.
 20. Anchouche S, Hall N, Bal S, et al. IRIS Registry Data Analytic Centers. Chemical and thermal ocular burns in the United States: An IRIS registry analysis. *Ocul Surf*. 2021 Jul;21:345-347.
 21. Ahmmed AA, Ting DSJ, Figueiredo FC. Epidemiology, economic and humanistic burdens of Ocular Surface Chemical Injury: A narrative review. *Ocul Surf*. 2021 Apr;20:199-211.
 22. Macdonald EC, Cauchi PA, Azuara-Blanco A, Foot B. Surveillance of severe chemical corneal injuries in the UK. *Br J Ophthalmol*. 2009 Sep;93(9):1177-1180.
 23. Chau JP, Lee DT, Lo SH. A systematic review of methods of eye irrigation for adults and children with ocular chemical burns. *Worldviews Evid Based Nurs*. 2012 Aug;9(3):129-138.
 24. Laursen JV, Hjortdal JØ. Akut behandling af kemiske øjenskader [Evidence for emergency treatment of chemical eye burns]. *Ugeskr Laeger*. 2014;176(34):V04130213.
 25. Kim JC, Tseng SC. Transplantation of preserved human amniotic membrane for surface reconstruction in severely damaged rabbit corneas. *Cornea*. 1995 Sep;14(5):473-484.
 26. Fish R, Davidson RS. Management of ocular thermal and chemical injuries, including amniotic membrane therapy. *Curr Opin Ophthalmol*. 2010 Jul;21(4):317-321.
 27. Meller D, Pires RT, Mack RJ, et al. Amniotic membrane transplantation for acute chemical or thermal burns. *Ophthalmology*. 2000 May;107(5):980-9; discussion 990.
 28. Shanbhag SS, Basu S. Commentary: The role of amniotic membrane transplantation in the management of acute ocular chemical burns. *Indian J Ophthalmol*. 2021 Jan;69(1):64-65.
 29. Clare G, Suleman H, Bunce C, Dua H. Amniotic membrane transplantation for acute ocular burns. *Cochrane Database Syst Rev*. 2012 Sep 12;2012(9):CD009379.
 30. Barros A, Queiruga-Piñeiro J, Lozano-Sanroma J, et al. Small fiber neuropathy in the cornea of Covid-19 patients associated with the generation of ocular surface disease. *Ocul Surf*. 2022 Jan;23:40-48.
 31. Ralph RA. Tetracyclines and the treatment of corneal stromal ulceration: a review. *Cornea*. 2000 May;19(3):274-7.
 32. Sinisi F, Della Santina M, Loiudice P, Figus M, Casini G. The Role of Silicone Oil in the Surgical Management of Endophthalmitis: A Systematic Review. *J Clin Med*. 2022 Sep 16;11(18):5445.
 33. Masroor, Saqib. Collateral damage of COVID-19 pandemic: delayed medical care. *Journal of cardiac surgery*, 2020, 35.6: 1345-1347.
 34. Gertz, Autumn H., et al. Delayed medical care and underlying health in the United States during the COVID-19 pandemic: A cross-sectional study. *Preventive Medicine Reports*, 2022, 28: 101882.
 35. Erdem S, Karahan M, Ava S, Dursun ME, Hazar L, Keklikci U. Examination of the effects of COVID 19 on corneal endothelium. *Graefes Arch Clin Exp Ophthalmol*. 2021 Aug;259(8):2295-2300.