

to as DRPE, and is typified by a varying scope of atrophic RPE lesions, with or without detachment of the neuroretina [84].

5. Inactive CSC: Cases with a medical history of CSC episodes, though currently without signs of SRF.

In addition to the above basic types, there is also a smaller group of patients who have the following atypical clinical picture in CSC:

Atypical CSC: In advanced chronic forms (persisting for several years), in addition to persistent serous ablation of the neuroretina and multiple atrophic RPE lesions, there may also be presence of cystoid macular degeneration [76], multifocal CSC [85] or flat irregular ablation of the RPE ("wavy RPE"), beneath which there may be presence of incipient secondary type I CNV [86,87]. CNV upon a background of CSC is generally not entirely clearly demonstrated on FAG, and in many cases also not on ICG, though it may now be detected with a high degree of sensitivity and specificity with the aid of OCT-A [88,89].

Bullous CSC: A rare clinical variant of chronic CSC is bullous serous retinal detachment (Fig. 1). Due to the influence of gravity, the maximum SRF tends to be located in the inferior quadrants, and in some cases we may find massive deposits of subretinal fibrin [90].

EXAMINATION METHODS FOR CSC

Examination of visual acuity

Examination of VA ranks among the fundamental and most important functional ocular examinations. In regular practice Snellen charts are most commonly used,

though these do not enable standardized examination, the change of letter size between rows is not regularly progressive, and the letters have varying degrees of difficulty of legibility. A more precise determination of VA is attained by the use of ETDRS optotypes. Their advantage is the same number of letters in the row, the same degree of legibility of the individual characters, in which they maintain geometric progression of the size of optotypes in individual rows. Repeated testing demonstrates very positive results in comparison with the Snellen method, and this can be used in clinical research, providing more detailed (sensitive) changes of values of visual acuity in the observed period.

Biomicroscopic examination of the ocular fundus

In biomicroscopic examination of a patient with CSC, we detect typical detachment of the neuroretina, which is evident as a sharply bordered, transparent "blister" on the posterior pole of the eye. As a rule, the foveal reflex is not generally evident, and is rather replaced by a "halo effect" resulting from the reflection of the light from the detached neuroretina. In the place of detachment, the retina is of normal thickness, without any change in transparency. The fovea may manifest a slightly yellowish color in the biomicroscopic image due to the visible xanthophyll of the central part of the retina. Numerous yellowish-white fibrin deposits may be present, covering the posterior surface of the elevated neuroretina [23]. Typical manifestations are irregularities of the RPE, which are accentuated with chronicity of the condition. Upon rigorous biomicroscopy (subsequently verified with the

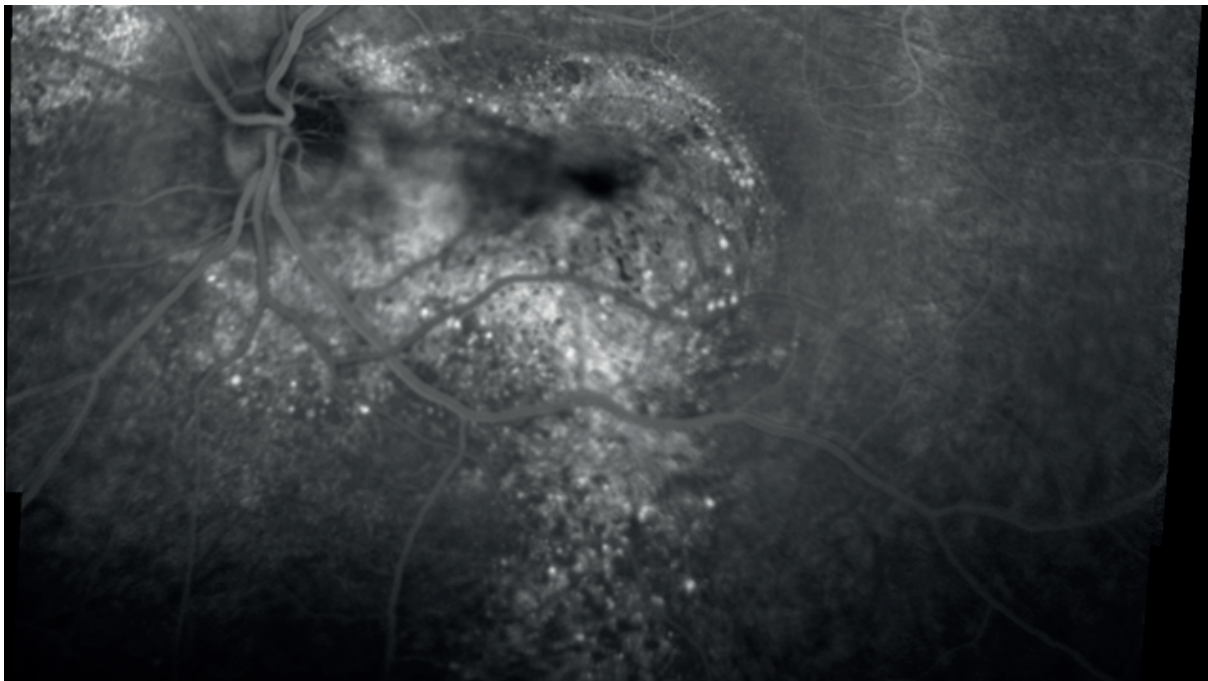


Figure 2. Fluorescein angiography of a 54-year-old patient with a chronic form of central serous chorioretinopathy (Heidelberg Spectralis, Myslík Manethová): late venous phase of wide-field angiography showing a wide area of diffuse disintegration of the retinal pigment epithelium layer and a typical gravity trace above the terrain of dystrophically altered retinal pigment epithelium after long-term subretinal exudation

aid of OCT) we may find one or more loci of serous detachment of the RPE. In the case of a long duration of the disease, the subretinal fluid may stimulate fibrotic changes, which may lead to permanent functional changes. However, in the majority of cases a gradual resorption of fibrin deposits takes place. Conditions predisposing to exudation of fibrin are extensive or numerous PEDs (RPE ablations), chronic or recurrent form of the pathology, systemic treatment with corticosteroids, pregnancy and organ transplantation [23].

Excessive exudation may lead as far as bullous serous retinal detachment, with maximum in the inferior quadrants [90]. Chronic forms are typified rather by flat serous separation of the neuroepithelium above areas of the dystrophic altered RPE, which in places may progress as far as flat atrophy. These atrophies are most commonly found in the macular and peripapillary zone, and “trickle” downwards due to the influence of gravity upon chronic exudation (Fig. 2) [91].

IMAGING METHODS OF CSC

Color fundus photography

Instruments enabling the recording of an image of the retina on classical or digital photography are founded on a similar imaging principle as indirect ophthalmoscopy. A photograph of the ocular fundus is appropriate for evaluating the condition, monitoring the progression and effect of treatment of the pathology. At present the method is being progressively replaced by techniques which identify the current clinical finding and its development over time in greater detail (OCT, FAG/ICG, OCT-A). Nevertheless, color photography of the ocular fundus retains its place especially in the photographic documentation of atypical or rare forms of CSC.

Fluorescein angiography

We consider fluorescein angiography to be the oldest and also the fundamental examination technique for determining the diagnosis, evaluating the finding and excluding other differential diagnoses in CSC. FAG is an invasive imaging method, which serves to examine the flow of blood in particular through the retinal and to a lesser degree also choroidal vascular bed, with the use of a contrast substance applied intravenously (fluorescein sodium salt). The examination provides dynamic information about the condition of the inner and outer blood-ocular barrier, and partially also about the condition of the RPE layer.

A characteristic finding in the early phase of the angiogram is the presence of one or several sources of fluorescein leakage on the level of the defective RPE, with progressively increasing fluorescence and scope into the late venous phase, referred to as “inkblot”. In approximately 10% of cases a typical “smokestack” formation is visible, in which the dye gradually diffuses into the space of serous detachment of the neuroretina, thereby creating an image similar to rising “smoke from a smokestack” [23].

In chronic forms of the disease, it may be the case that no unambiguous point sources of hyperfluorescence are identified, but rather areas with a diffuse window defect in the early phases, and increased diffused fluorescence in the late phases of the angiogram, which are evident in diffuse atrophic changes of the RPE in the chronic stages of the pathology. According to the character of the finding and the dynamic changes during the course of the angiogram, it is possible to assess the degree of activity of the pathology and thus to select an adequate therapeutic approach [48,92–94]. Cystoid macular degeneration or CNV upon a background of CSC may not necessarily be entirely demonstrable on FAG, and it is therefore always a benefit to use multimodal imaging due to the greater probability of identifying all the abnormalities and determining the correct diagnosis [76,89].

FAG is considered the fundamental examination method for this pathology, and serves as a template for any applicable treatment of the retina by a laser coagulation beam in the place of point hyperfluorescence recorded in the early phase of the angiogram, or by a thermal laser stimulation beam in photodynamic therapy in the place of diffused hyperfluorescence in the late phases of the angiogram. FAG is also beneficial in differential diagnostics, and enables the exclusion of pathologies which have a similar clinical picture to CSC (Vogt-Koyanagi-Harada syndrome, CNV upon a background of ARMD, infectious disease of the posterior segment of the eye etc.).

Indocyanine green angiography (ICG)

ICG angiography has expanded our knowledge about the pathogenesis of this disease. Thanks to its properties, it detects particularly deeper layers – the choroid – thus the place of origin of the pathology. The principle of examination is identical to the procedure upon fluorescein angiography, with the only difference that the dye used is indocyanine green, which binds very quickly to blood plasma proteins (98%). After exposure through excitation light, ICG emits a fluorescent light with a wavelength within the range of 805–835 nm, which explains the relatively high transmission through the ocular tissue (xanthophyll and melanin of the RPE, opalescent lens, choroid). For this reason, ICG angiography is appropriate for visualization of the choroidal vascular network, and therefore offers a precise evaluation of the extent of the choroidal lesion in patients with CSC [48,55,56]. In the early phase of the angiogram, as a rule a delay appears in the filling of the choroid; early hyperfluorescence attests to choriocapillaris nonperfusion. This leads to dilation of the choroidal veins, which in the mid phase of the angiogram is displayed as geographical area of increased fluorescence due to hyperpermeability, especially of the large choroidal vessels, known as the Haller’s layer. Areas of hyperfluorescence expand centrifugally into the venous phase, and may not be strictly localized only in places corresponding to places of hyperfluorescence visible upon FAG examination (on the contrary, very often they may be observed in places which appear to be clinica-

lly normal, or in the contralateral, unaffected eye). In the late venous phase, the dye is either washed out of the tissue or hyperfluorescence persists, which among other factors depends on the degree of activity of the pathology [48,55,92–95]. An unequivocal advantage is the performance of simultaneous FAG and ICG, with a mutual comparison thereof. Choroidal vascular hyperpermeability is a common feature of all forms of CSC [94,95]. However, the areas of hyperfluorescence (activity) in FAG very often do not entirely correspond to the areas of increased activity demonstrated with the aid of ICG (Fig. 3). For this reason, it may be possible for us to determine the development of activity better through a mutual comparison than by performing the methods separately.

ICG imaging is an essential examination method before planned PDT, and provides us with the entirely exact scope, frequency and localization of the choroidal lesion, which may not always be visible on the FAG image. Similarly, ICG has an irreplaceable role in cases of unsatisfactory response to treatment or if CSC has a recurrent course, in which other choroidal lesions may be activated over the course of time [96].

Optical coherence tomography

Thanks to spectral domain OCT (SD-OCT) and more recently also thanks to enhanced depth imaging OCT (EDI-OCT) and en face swept-source OCT (SS-OCT), which enable the imaging of retinochoroidal tissue throughout its entire thickness, we are now better able to understand the anatomy and partially also the pathophysiology of CSC. OCT is a contactless, noninvasive, nonmydriatic, safe,

fast and effective examination method, which is used as the method of first choice for the quantitative evaluation of CSC, monitoring of the development and effect of treatment. It is a highly specialized examination of the macula on the principle of low-coherence interferometry with high resolution, which in the form of an incision enables the imaging of not only retinal but also choroidal structures, with a high-resolution capacity of up to 3 μm [97]. Thanks to its high-resolution capacity it provides detailed information about the structures on the level of the vitreoretinal interface, the individual layers of the retina, RPE, Bruch's membrane, and by means of current options also the individual layers of the choroid. A typical finding on OCT in CSC is the presence of hyporeflective (non-reflective) fluid beneath the layer of the RPE and neuroepithelium. Elongation and thickening of the outer segments of the photoreceptors occur in the place of serous detachment of the neuroretina, and in places also their erosion, ensuing as an abrasion mechanism upon pronounced exudative activity above the RPE defect [79]. In 50–100% of cases of CSC, RPE ablation is present [98,99]. Various high RPE ablations of a serous character are typical of early forms of the disease, and appear most frequently above places of increased choroidal permeability [79]. In the case of chronic lesions, we rather observe irregular flat undulation of the RPE layer, and the presence of dense (hypo- and hyperreflective) material between the Bruch's membrane and the RPE, which on OCT imaging creates a "double layer sign" [99,100]. Another sign of rather chronic lesions is hyperreflective foci visible in the retinal layers, in

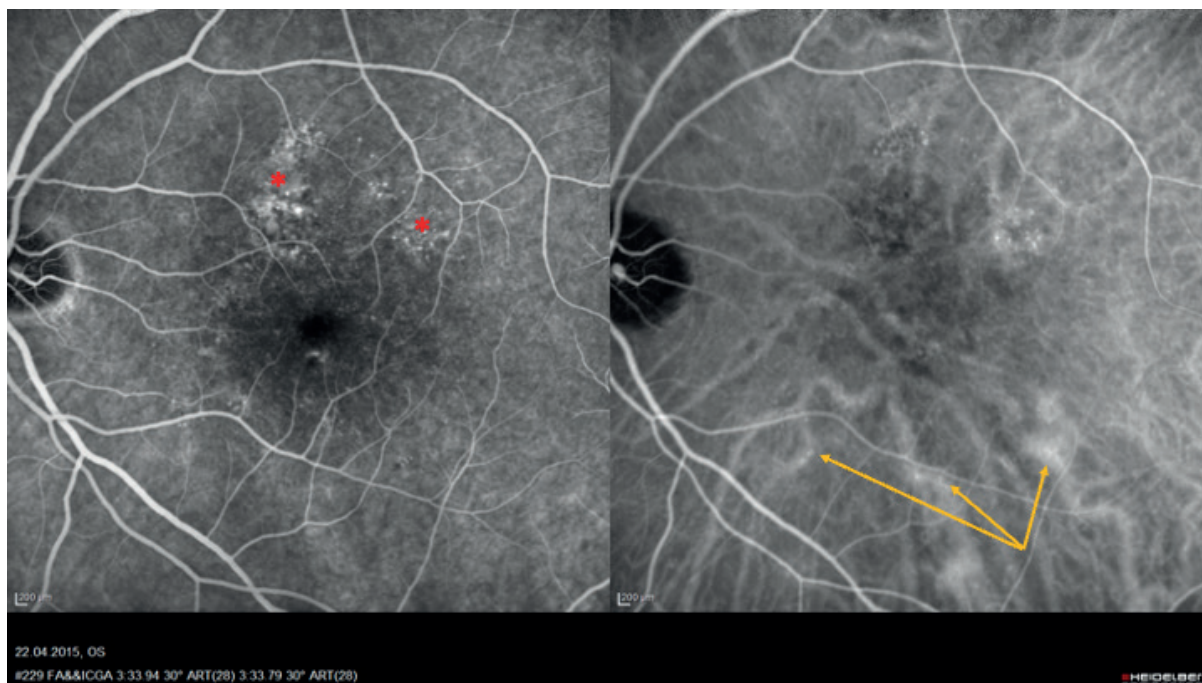

Figure 3. Simultaneous fluorescein and indocyanine green angiographic image in a 58-year-old patient with a multifocal chronic form of central serous chorioretinopathy (Heidelberg Spectralis, Myslík Manethová): the middle phase of the angiogram with increased fluorescence of the pathologically changed retinal pigment epithelium at the upper temporal arcade (*red asterisk*); on indocyanine green angiography, 3 significantly dilated and leaking large choroidal vessels of Haller's layer are visible in the inferior temporal arcade, but they are not visible on fluorescein angiography (*yellow arrows*)

the subretinal space and in the region of the inner choroid, which correspond with hyperautofluorescent deposits evident on the retina [101–103]. It appears that a greater quantity of hyperreflective foci correlates with a longer duration of the disease and a worse prognosis of resulting VA [104]. In the case of recurrent or several-year duration of the pathology, we may often find cystoid macular degeneration (CMD) on OCT scans, as well as thinning of the outer nuclear layer (ONL) of the retina, disruption of the ellipsoid zone (the junction between the outer and inner segments of the photoreceptors) or the external limiting membrane (ELM), an absence of photoreceptors or general atrophy of the retinal layers [102].

In comparison with the healthy population, EDI-OCT demonstrated a generally greater thickness of the choroid and larger choroidal vessels of the Haller's layer in patients with CSC, as well as conversely thinning of the Sattler's layer together with the choriocapillaris in both the affected and the contralateral eye; this is probably caused both by the pressure of dilated vessels and by primary atrophy of the choriocapillaris upon hypoperfusion of the tissue [99,105]. Change of choroidal thickness may be focal or diffuse, and may not necessarily entirely correlate with areas of hyperfluorescence on ICG in the places of vascular hyperpermeability of the Haller's layer [106]. These findings further confirm the idea that CSC may be caused by locally increased hydrostatic pressure of the choroid [4,28,105,107]. With regard to the thickness of the choroid, according to the current nomenclature CSC is classified among pachychoroid diseases (together with pachychoroid pigment epitheliopathy, pachychoroid neovasculopathy, polypoidal choroidal vasculopathy, and focal choroidal excavation) [24] (Fig. 4).

Optical coherence tomography angiography

OCT-A is a new, promising, noninvasive method, with the aid of which it is possible to examine the retinal and choroidal vascular network without the use of an intravenous contrast substance, with high-resolution capacity in all layers of the retina and choroid. The principle of OCT-A is to detect the movement of particles; on the assumption that the only moving particles in an otherwise motionless eye are blood elements (erythrocytes). It therefore concerns the recording of blood flow in the vessels of the retina and choroid. OCT-A images may be evaluated summarily or in isolation in the individual vascular layers, which enables a very detailed analysis of the vasculature on various levels without blurring of the structures, as tends to be the case upon leakage or accumulation of dye in classic FAG [89]. On OCT-A images we usually detect abnormal flow through the large, dilated vessels of the choroid and the dilated vessels of the choriocapillaris. An abnormal flow of the choriocapillaris, which is manifested as a dark zone on the image, attest to a reduction of flow correlating with the finding on ICG in acute, but especially in chronic forms [108].

Costanzo et al. described 3 specific findings on OCT-A in the region of the choriocapillaris: dark areas, dark points and abnormal choroidal vessels. The dark areas are described as diffuse or focal, rough, imprecisely bordered regions with a low or undetectable flow, whereas the dark points are black, individual or multiple sharply bordered deposits without any detectable blood flow on the level of the choriocapillaris. The dark areas mostly correspond to the zones of SRF, whereas the dark points correspond with ablations of the RPE. Abnormal choroidal vessels are described as

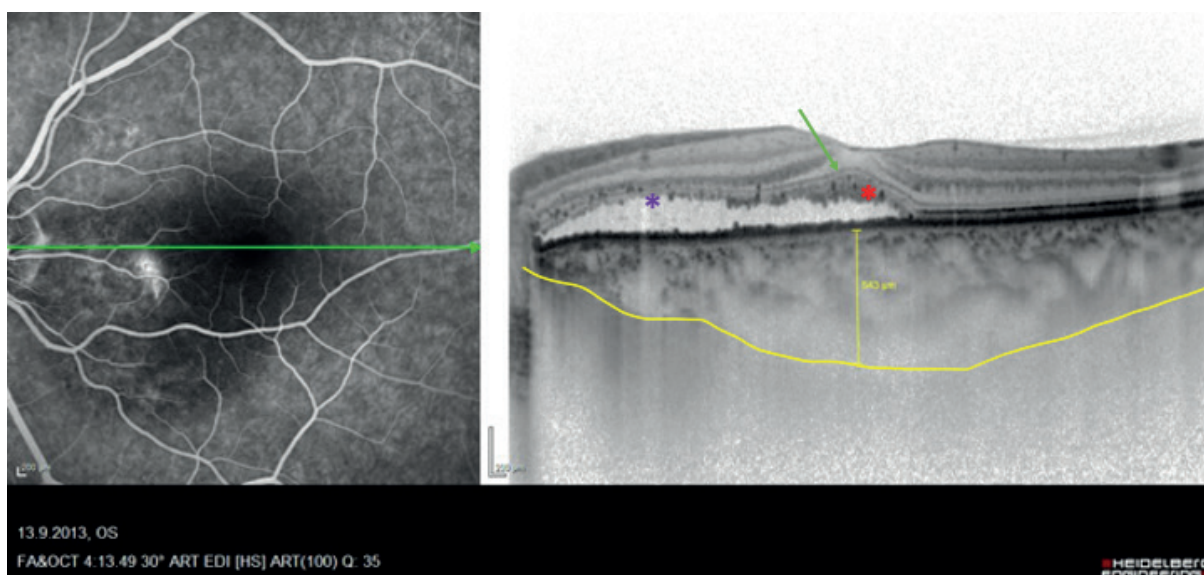


Figure 4. Combined image of fluorescein angiography and transfoveolar linear scan of optical coherence tomography (Heidelberg Spectralis, Myslík Manethová) of a 48-year-old patient with chronic long-lasting central serous chorioretinopathy with typical elongation and thickening of photoreceptors, hyperreflective dots present (*red asterisk*), preserved external limiting membrane (*green arrow*), marked by noticeably dilated lobular choroid (*yellow*) and focal abrasion of photoreceptors in the maculopapillary bundle (*purple asterisk*)

manifest, clearly delineated, intricate dilated vessels with a large flow. The interpretation of these abnormal choroidal vessels should be conducted with caution, because in many cases it is not easy to differentiate them from the choroidal neovascular network [89,109]. Furthermore, today OCT-A far better enables us to detect the presence of secondary CNV, usually appearing beneath an irregularly undulating RPE, which is not very often detectable on FAG or ICG examination [87,89,110,111]. OCT-A is thus becoming an entirely revolutionary imaging method, which provides us not only with relatively exact information about the structure, but also indirectly about the function of the retinochoroidal tissue, and should therefore always be included upon the examination especially of chronic forms of CSC.

Fundus autofluorescence (FAF)

Autofluorescence, a noninvasive imaging method, has gained substantial popularity in the last decade. It is the only examination technique to enable the detection of the metabolic activity of physiologically or pathologically present fluorophores of the retina in vivo (e.g. lipofuscin granules, collagen, elastin, fibrin), thus structures distinguished by varying degrees of autofluorescence. During the examination 2 types of FAF examination may be applied: short-wave FAF (SW-FAF) or near-infrared FAF (NIR-FAF). SW-FAF is irradiated by lipofuscin granules of

the RPE and thereby provides information about the condition of the RPE. NIR-FAF originates from melanin pigment of the choroid and RPE. Although NIR-FAF is used less frequently, clinical trials have demonstrated that in the case of CSC it may be far more sensitive in detecting changes of the outer retinal layers [112,113].

Physiological FAF is typified by dark imaging of the optic nerve and vessels due to the absence of autofluorescent fluorophores and homogenous autofluorescence of the RPE [93,114,115]. In eyes with acute CSC there is a characteristic mottled image of increased autofluorescence in the zone of the ablated sensory epithelium due to the presence of subretinal or intraretinal precipitates and deposits with an increased lipofuscin content (accumulation of the outer segments of the photoreceptors, which are not phagocytosed by the breached RPE, or an accumulation of macrophages with phagocytosed outer segments) [114]. In the early phase, areas of hypoautofluorescence are evident, corresponding with locations of leakage in 70–100% of cases, thus in the place of the defective RPE [116,117].

In chronic forms, as in acute forms, the majority of eyes manifest hypoautofluorescence in the place of leakage visible on FAG, which is due to the presence of subretinal fluid and varying degrees of damage to the RPE. The pathognomic finding in long-term states is mixed autofluorescence of varying intensity. Especially the zones above the dystro-

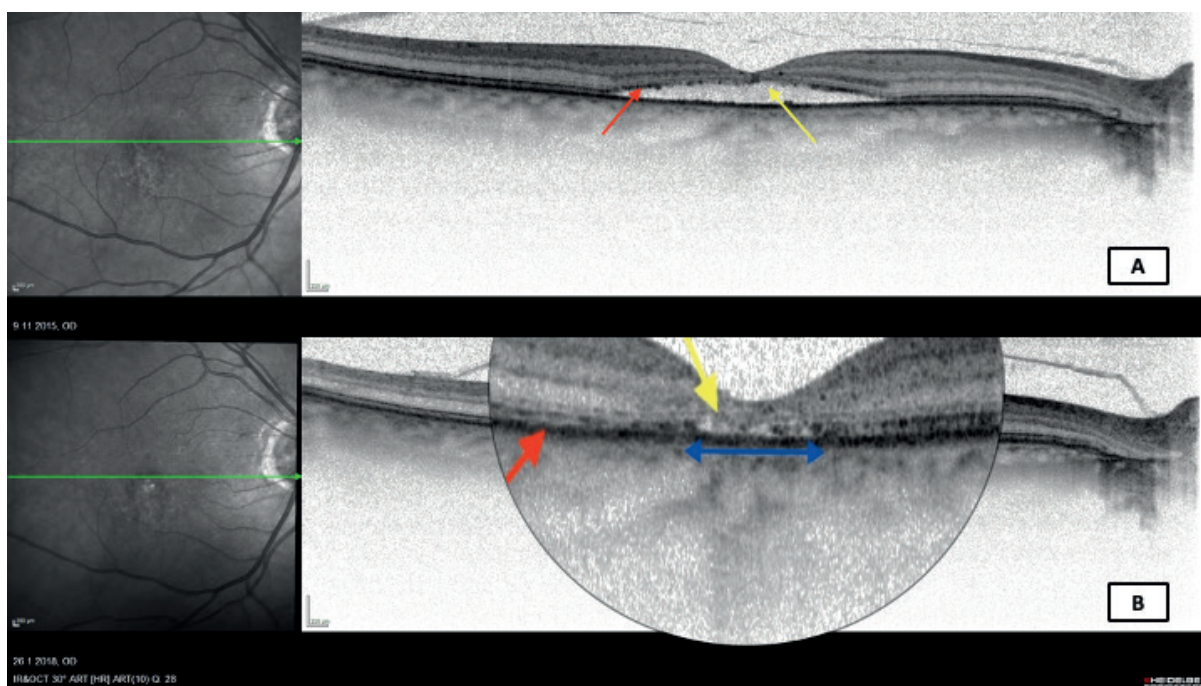


Figure 5. Transfoveal linear optical coherence tomography scan (Heidelberg Spectralis, Myslík Manethová) of a 61-year-old patient with chronic central serous chorioretinopathy showing: **(A)** flat serous detachment of neurosensory retina in the area of the central macula; at the edge of the detachment, the line of photoreceptors is still preserved (red arrow), while subfoveolarly, the line of photoreceptors is already absent due to the long-term presence of subretinal fluid (yellow arrow). **(B)** depicts the state after a photodynamic therapy with half the dose of verteporfin with a satisfactory anatomical effect, however, the transfoveal linear scan reveals total retinal atrophy in the central part of the macula with atrophy of the subfoveal retinal pigment epithelium layer above it (blue arrow) with a noticeable absence of the photoreceptor line (yellow arrow); and vice versa by a relatively well-preserved interdigitation zone at the edge of the original neuroretinal detachment (red arrow)