

# THE EFFECT OF CATARACT SURGERY ON THE REPRODUCIBILITY AND OUTCOME OF OPTICAL COHERENCE TOMOGRAPHY MEASUREMENTS OF MACULAR AND RETINAL NERVE FIBRE LAYER THICKNESS

## SUMMARY

**Introduction:** Optical coherence tomography (OCT) is a non-invasive imaging technique used for the examination of the macula and peripapillary retinal nerve fibre layer (RNFL), the result of which may be affected by the quality of the scanned image. The aim of our study was to assess the influence of uncomplicated cataract extraction on the measurement of macular and RNFL thickness with OCT and to determine the reproducibility of this method before and after cataract surgery in a group of healthy people. We also evaluated the effect of different intraocular lenses (IOL) (with/without yellow filter) on the reproducibility of the OCT examination.

**Methods:** The study group included 51 eyes of 51 patients who underwent cataract surgery with posterior chamber IOL implantation. Macular and RNFL thickness were measured with spectral domain OCT (Optovue, Model RT 100) one week before surgery, and postoperatively after one and six months. Three OCT scans were performed at each visit to assess the reproducibility of the measurement. Data were statistically processed.

**Results:** Analysis of the changes in macular and RNFL thickness showed a significant increase in retinal thickness, with the maximum increase one month after surgery, and regression of this thickening six months after surgery. Reproducibility of OCT examination improved significantly after cataract surgery, even though the preoperative values were of low coefficient of variance and therefore of high accuracy. No difference was found in the use of different intraocular lenses on the reproducibility of the OCT examination.

**Conclusion:** The presence of cataract affects the OCT measurement of macular and RNFL thickness. The reproducibility of the method significantly improves after cataract surgery. It is likely that the increase in macular and RNFL thickness after cataract removal is partly due to improvement in the quality of the scanned image and thus to the greater accuracy of the OCT examination.

**Key words:** optical coherence tomography, glaucoma, cataract, macular thickness, retinal nerve fibre layer thickness

Čes. a slov. Oftal., 72, 2016, No. 2, p. 20–26

## INTRODUCTION

Optical coherence tomography (OCT) is a non-invasive imaging method used in ophthalmology especially for the examination of the macula and peripapillary retinal nerve fibre layer (RNFL) (1-5).

With regard to the fact that this concerns an imaging method, the quality of imaging may be influenced by the non-transparency of the optic media (5). The most common cause of deteriorated transparency of the optic media is cataract. The more the cataract has progressed, the worse the quality of the scanned image, and the measured thickness of the retina or retinal nerve fibre layer may not correspond to the actual reality.

## STUDY AIM

The aim of our study was to assess the influence of uncomplicated cataract extraction on the measurement of macular and RNFL thickness using SD-OCT and to determine the re-

Pašová P.<sup>1,2</sup>, Skorkovská K.<sup>3</sup>

<sup>1</sup>Ophthalmology Centre Palánek, s.r.o., Vyškov

<sup>2</sup>GEMINI ophthalmology clinic a.s., Vyškov, head: MUDr. Pavel Stodůlka, Ph.D.

<sup>3</sup>Department of ocular pathologies and optometry, St. Anne University Hospital, Brno, senior consultant: MUDr. Lubomír Hanák

*The authors of the study declare that no conflict of interest exists in the compilation, theme and subsequent publication of this professional communication, and that it is not supported by any pharmaceuticals company.*



MUDr. Petra Pašová  
GEMINI oční klinika, a.s.  
Žerotínova 2  
682 01 Vyškov  
e-mail: pasova.petra@gmail.com

producibility of this method before and after cataract surgery in a group of healthy people. A second aim was to evaluate the effect of different intraocular lenses (IOL) (with/without yellow filter) on the reproducibility of OCT examination.

The study used spectral OCT by the Optovue company (RT-Vue, model R100), on which frequency (Fourier) domain technology or spectral analysis of signals (FD = Fourier Domain, SD = Spectral Domain) was used for the first time ever in 2006. This method has brought a great advance in the processing of the OCT image, because in comparison with previous Time Domain (TD) it has increased the speed of scanning and improved the resolution of the image.

## METHOD

The study group included patients before cataract surgery in whom the intensity of the cataract enabled biomicroscopic examination of the retina on a slit lamp and the performance of an OCT scan. The exclusion criteria covered: pre-

sence of retinal pathology, glaucoma, uveitis in anamnesis, condition following another intraocular operation or laser photocoagulation of the retina, condition following ocular trauma, perioperative complications upon cataract extraction on a postoperative cystoid macular edema.

Cataract surgery was performed by the standard technique of phacoemulsification with implantation of a posterior chamber intraocular lens into the lens capsule. Either a hydrophilic acrylate IOL without a yellow filter or one of two types of hydrophobic acrylate IOL with a yellow filter was used in implantation. The patients were examined one week before surgery and one and six months after surgery. At each visit an examination of natural and best corrected visual acuity for distance and near vision was conducted, as well as an examination of the anterior and posterior ocular segment in mydriasis, measurement of intraocular pressure using Goldmann applanation tonometry and OCT examination of the macula and RNFL in mydriasis on a RTVue-RT 100 instrument (Optovue, USA). In the assessment of reproducibility 3 macular scans and 3 RNFL scans were always taken for each eye.

For the examination of the macula an EMM5 scan was used, which covers the surface of the macula in dimensions of 6x6 mm with the help of 21 horizontal and 21 vertical B-scans. The map is divided into nine regions (fig. 1). For the examination of the RNFL, ONH NHM4 scanning was used. It is characterised by 12 radial scans with a length of 3.4 mm and 6 concentric circles with a diameter of 2.5 to 4.0 mm with the centre in the disc. The instrument determines the boundary of the papilla automatically. The thickness profile of the RNFL in the ONH scan represents the thickness of the RNFL at a distance of 3.45 mm from the centre of the disc (fig. 2, table 2) (6).

With regard to the normal distribution of data in the studied group, the mean values of the individual observed parameters with their standard deviations were used for the statistical calculations. Within the framework of the statistical evaluation, descriptive statistics of the studied group were compiled, with a comparison of the preoperative and postoperative best corrected visual acuity for distance and near vision. Changes in the thickness of the macula and RNFL were assessed with the help of a t-test. The reproducibility of the OCT examination was assessed using a coefficient of variation (COV). Examination methods with COV of less than 10% are considered reproducible, and in the case of a COV lower than 5% reproducible with a high rate of reliability (7). Changes in the reproducibility of OCT following cataract surgery were evaluated using a t-test. Differences in reproducibility of the OCT examination in patients with various types of implanted IOL were also assessed with the help of a t-test. For all tests the level of significance was set at  $\alpha = 5\%$ .

## RESULTS

The studied group originally included 54 patients (28 women and 26 men). Cystoid macular edema developed in 3 of the patients after surgery. These patients were not included in the statistical processing of the results, to eventually only 51 patients were evaluated. The average age of the patients in the group was 72.3 years (49-85 years  $\pm$  7.42 SD). No complications requiring exclusion of a patient from the study occurred in any

of the patients during the course of the operation. The values of best corrected visual acuity for distance and near vision, as well as of intraocular pressure, before surgery and one and six months after surgery are summarised in table 1.

### Development of macular thickness after cataract surgery

In the studied group an analysis of retinal thickness in the macula demonstrated a significant increase in retinal thickness ( $p < 0.05$ ) following cataract surgery in comparison with the preoperative period, in all the evaluated regions of the macula. Retinal thickness reached its maximum values one month after surgery, with a regression of thickening in the sixth postoperative month. Nevertheless, with the exception of the T2 region, macular thickness six months after surgery was statistically significantly larger than before surgery (table 3, graph 1).

### Reproducibility of measurement of macular thickness after cataract surgery

The reproducibility of measurement was evaluated using a coefficient of variability (COV). OCT examination of the macula in our studied group was accompanied by a low degree of variability (small range of values of macular thickness in three repeated measurements) and thus a high level of precision or reproducibility of the method before and after cataract surgery ( $COV < 5\%$ ). Despite this, in the majority of measurements, a statistically lower COV was recorded after surgery than before surgery ( $p < 0.05$ ) (table 4).

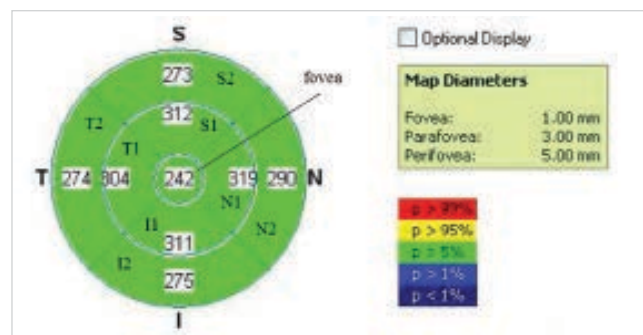


Fig. 1 Sample of scan EMM5 with description of individual regions

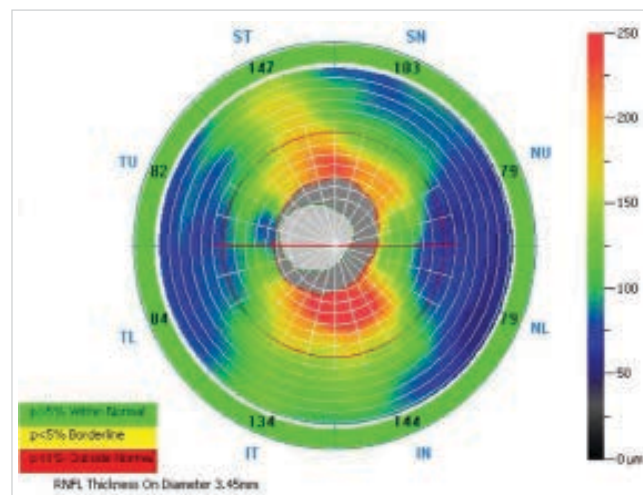


Fig. 2 Sample of scan ONH NHM4 with description of individual regions

**Table 1** Visual acuity and intraocular pressure in the studied group. Stated mean values and their standard deviations. BCDVA = Best Corrected Distance Visual Acuity, BCNVA = Best Corrected Near Visual Acuity

	Before surgery	1M after surgery	6M after surgery
Intraocular pressure (mmHg)	14.96 (2.92)	12.42 (2.47)	12.6 (2.28)
BCDVA	0.472 (0.19)	0.952 (0.08)	0.964 (0.07)
BCNVA	0.48 (0.13)	0.98 (0.06)	0.98 (0.06)

**Table 2** Description of measured regions

TU	Temporal Upper
ST	Superior Temporal
SN	Superior Nasal
NU	Nasal Upper
NL	Nasal Lower
IN	Inferior Nasal
IT	Inferior Temporal
TL	Temporal Lower

#### Development of RNFL thickness after cataract surgery

After cataract surgery there was an increase in RNFL thickness in all the observed regions in the studied group. RNFL thickness reached its maximum one month after surgery, with regression of thickness in the six postoperative month. RNFL thickness at the individual examinations and in the individual evaluated regions is illustrated in table 3. Upon a comparison of RNFL thickness before surgery and one month after surgery there was a statistically significant difference in all regions ( $p < 0.05$ ), with the exception of the SN region ( $p = 0.288$ ), localisation is evident from fig. 1. Upon a comparison of the measurements before surgery and six months after surgery a significant difference was found only in regions TU, ST and TL ( $p < 0.05$ ). Upon a comparison of measurements one and six months after surgery a statistically significant difference was determined in regions TU, NU, NL,

IN and IT ( $p < 0.05$ ), in the other regions no statistically significant difference in RNFL thickness was found (table 5).

#### Reproducibility of measurement of RNFL thickness after cataract surgery

The reproducibility of OCT evaluation of RNFL thickness demonstrated relatively low variability and thus a high level of precision of measurement (reproducibility) before ( $COV < 10\%$ ) and after cataract surgery ( $COV < 5\%$ ). In all patients in the studied group, a statistically lower COV was recorded after surgery than before surgery ( $p < 0.05$ ). Upon a comparison of measurements one and six months after surgery a statistically significant difference in the reproducibility of OCT was observed only in certain regions (TU, NL, IN and IT, localisation is evident from fig. 2). Reproducibility of OCT examination of the retinal nerve fibre layers at the individual examinations is illustrated in table 6.

#### Influence of type of implanted lens on reproducibility of OCT examination

A lens with a blue light filter was implanted in 39.6% of eyes in the studied group, a lens without a filter in 60.4% of eyes. We did not succeed in demonstrating the influence of the type of implanted intraocular lens on the reproducibility of OCT measurement ( $p > 0.05$ ).

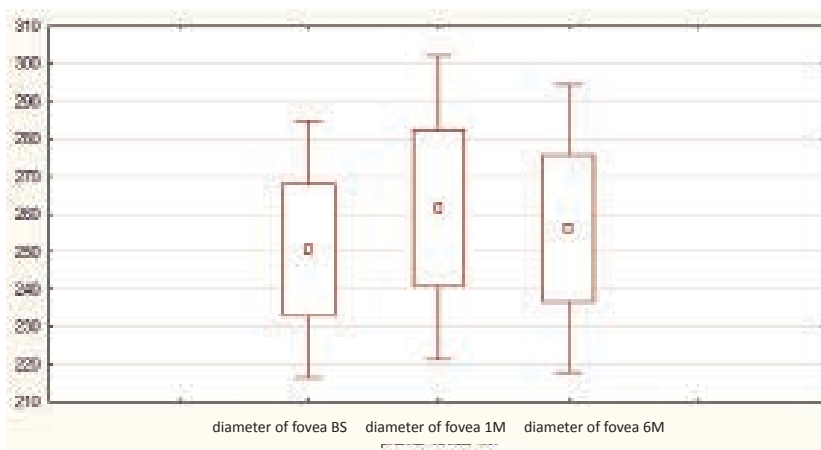
## DISCUSSION

OCT examination has become the standard in diagnosis and observation of changes in the macula and on the disc of the optic nerve. In a range of patients with macular pathology or glaucoma, the precision of the examination may be influenced by the reduced transparency of the optic media,

**Table 3** Retinal thickness in the macula in the studied group during the course of the study. Stated mean values and their standard deviation ( $\mu\text{m}$ )

Region	Before surgery	1M after surgery	6M after surgery	p1	p2	p3
fovea	250.5 (17.49)	261.49 (20.64)	256.14 (19.5)	0.000	0.000	0.002
S1	308.76 (18.33)	318.46 (19.52)	313.3 (19.48)	0.000	0.000	0.000
N1	309.69 (18.72)	319.74 (21.9)	315.76 (19.83)	0.000	0.000	0.000
I1	304.65 (16.85)	313.81 (18.7)	308.81 (18.57)	0.000	0.000	0.000
T1	298.53 (17.00)	307.50 (18.10)	302.42 (17.93)	0.000	0.002	0.000
S2	276.15 (15.62)	283.53 (16.36)	279.13 (16.60)	0.000	0.001	0.000
N2	291.19 (20.49)	301.22 (22.63)	296.13 (22.20)	0.000	0.000	0.000
I2	269.85 (17.78)	278.89 (19.67)	273.77 (19.18)	0.000	0.000	0.000
T2	270.93 (16.05)	277.12 (18.91)	272.84 (17.59)	0.000	0.089	0.005

Statistically significant differences are indicated in red ( $p < 0.05$ ); p1 – comparison of measurements before surgery and 1 month after surgery, p2 – comparison of measurements before surgery and 6 months after surgery, p3 – comparison of measurements 1 month and 6 months after surgery



**Graph 1** Retinal thickness in region of fovea in the studied group during the course of the study; BS – before surgery, 1M 1 month after surgery, 6M – 6 months after surgery

most frequently cataract. The aim of our study was to determine the influence of cataracts on the reproducibility, thus the precision of OCT measurement of the thickness of the macula and peripapillary retinal nerve fibre layer, as well as to observe any applicable changes in the thickness of the macula and RNFL in the perioperative period.

The reproducibility of OCT examination of the macula and retinal nerve fibre layer was high in our study already before cataract surgery, although after surgery there was a significant further increase. The improvement in the reproducibility of OCT examination can certainly be attributed to the higher strength of the signal and therefore the better quality of the scan after removal of the turbid lens.

Spanish ophthalmologists have also studied the influence of cataracts on the result of OCT examination, evaluating the influence of uncomplicated cataract on measurement of the thickness of the macula and RNFL in healthy individuals using two different SD-OCT (Cirrus and Spectralis). Their study included 60 eyes of 60 healthy individuals who underwent cataract surgery with the help of phacoemulsification. One month before and one month after surgery three scans were performed on each instrument, focusing on the macula and RNFL. Reproducibility was evaluated using a calculation of COV. RNFL thickness before and after surgery was different upon measurement on both tested OCT instruments, in the majority of the evaluated regions the difference was statistically significant ( $p < 0.05$ ). Macular thickness measured using OCT Spectralis did not differ before and after surgery, but on the Cirrus instrument statistically significant differences were determined. Reproducibility of measurement was greater after cataract removal, nevertheless the change in the coefficient of variability was recorded only in the case of the Cirrus instrument. The authors state that the presence of a cataract influences measurement of the thickness of the macula and RNFL using SD-OCT, especially in the case of the Cirrus instrument (8).

In addition to the influence of cataract on reproducibility of OCT measurement, in the study we also evaluated the natural development of changes in macular and RNFL thickness following uncomplicated cataract surgery. The largest increase in the thickness of the entire macular region and the retinal nerve fibre layer occurred one month after surgery, in the sixth postoperative month macular and RNFL thickness was reduced, though not to its original level, and the difference between the preoperative values remained

ability was evaluated using a calculation of COV. RNFL thickness before and after surgery was different upon measurement on both tested OCT instruments, in the majority of the evaluated regions the difference was statistically significant ( $p < 0.05$ ). Macular thickness measured using OCT Spectralis did not differ before and after surgery, but on the Cirrus instrument statistically significant differences were determined. Reproducibility of measurement was greater after cataract removal, nevertheless the change in the coefficient of variability was recorded only in the case of the Cirrus instrument. The authors state that the presence of a cataract influences measurement of the thickness of the macula and RNFL using SD-OCT, especially in the case of the Cirrus instrument (8).

**Table 4** Reproducibility of OCT examination of macular thickness in the studied group during the course of the study.

Region	Before surgery	1M after surgery	6M after surgery	p1	p2	p3
fovea	1.07 (0.83)	0.5 (0.24)	0.51 (0.26)	0.000	0.000	0.920
S1	0.6 (0.43)	0.42 (0.23)	0.73 (2.54)	0.010	0.727	0.400
N1	0.71 (0.5)	0.62 (2.27)	0.37 (0.18)	0.630	0.000	0.180
I1	0.65 (0.41)	0.48 (0.27)	0.42 (0.18)	0.020	0.001	0.232
T1	0.7 (0.46)	0.46 (0.3)	0.4 (0.19)	0.005	0.000	0.159
S2	0.587 (0.38)	0.51 (0.62)	0.43 (0.21)	0.410	0.010	0.420
N2	0.65 (0.49)	0.38 (0.23)	0.42 (0.21)	0.002	0.001	0.438
I2	0.97 (0.86)	0.45 (0.23)	0.46 (0.23)	0.000	0.000	0.820
T2	0.91 (0.73)	1.00 (3.62)	0.77 (1.9)	0.869	0.628	0.696

Stated mean values of coefficient of variation (COV in %) and their standard deviation. Statistically significant differences are indicated in red ( $p < 0.05$ ); p1 – comparison of measurements before surgery and 1 month after surgery, p2 – comparison of measurements before surgery and 6 months after surgery, p3 – comparison of measurements 1 month and 6 months after surgery

**Table 5** RNFL thickness in the studied group during the course of the study. Stated mean values and their standard deviation (µm)

Region	Before surgery	1M after surgery	6M after surgery	p1	p2	p3
TU	76.86 (12.08)	83.4 (12.0)	81.52 (12.44)	0.000	0.000	0.000
ST	134.97 (15.65)	141.49 (18.6)	138.92 (16.74)	0.000	0.008	0.052
SN	122.7 (21.38)	124.44 (21.39)	122.47 (20.12)	0.288	0.905	0.192
NU	77.22 (14.6)	80.74 (15.69)	77.92 (12.42)	0.004	0.613	0.016
NL	69.42 (13.52)	72.56 (12.63)	70.02 (10.87)	0.009	0.692	0.021
IN	116.95 (20.57)	120.27 (20.94)	117.06 (21.07)	0.045	0.953	0.031
IT	138.25 (18.33)	143.44 (19.15)	140.75 (17.47)	0.000	0.120	0.041
TL	69.08 (10.52)	74.91 (11.67)	74.44 (11.78)	0.000	0.000	0.659

Statistically significant differences are indicated in red ( $p < 0.05$ ); p1 – comparison of measurements before surgery and 1 month after surgery, p2 – comparison of measurements before surgery and 6 months after surgery, p3 – comparison of measurements 1 month and 6 months after surgery

**Table 6** Reproducibility of OCT examination of RNFL thickness in the studied group during the course of the study.

Region	Before surgery	1M after surgery	6M after surgery	p1	p2	p3
TU	5.39 (2.27)	2.89 (0.97)	2.53 (0.87)	0.000	0.000	0.005
ST	3.56 (1.93)	1.72 (0.73)	1.5 (0.52)	0.000	0.000	0.058
SN	3.92 (2.08)	2.1 (0.96)	2.07 (0.91)	0.000	0.000	0.809
NU	5.53 (3.43)	2.85 (1.42)	2.94 (1.23)	0.000	0.000	0.467
NL	6.26 (2.92)	3.55 (1.56)	2.91 (1.36)	0.000	0.000	0.008
IN	3.9 (2.21)	2.34 (1.08)	1.97 (0.88)	0.000	0.000	0.011
IT	3.44 (1.74)	1.82 (0.91)	1.49 (0.64)	0.000	0.000	0.026
TL	5.5 (3.24)	2.88 (1.33)	2.52 (1.12)	0.000	0.000	0.074

Stated mean values of coefficient of variation (COV in %) and their standard deviation. Statistically significant differences are indicated in red ( $p < 0.05$ ); p1 – comparison of measurements before surgery and 1 month after surgery, p2 – comparison of measurements before surgery and 6 months after surgery, p3 – comparison of measurements 1 month and 6 months after surgery

statistically significant.

The dynamic of changes in the macular region following cataract surgery has been the subject of a range of studies, of which most, like us, observed macular thickening in the early postoperative period. For example, in their study Cagini et al. observed changes in the macula following uncomplicated cataract surgery in otherwise healthy eyes. Three months after surgery an asymptomatic increase in retinal thickness was recorded in the macular region. No correlation was found between macular thickness and visual acuity (9). The influence of phacoemulsification on the incidence of macular edema in patients without diabetes and in diabetics without symptoms of diabetic retinopathy was determined in a study by Jurečka et al. In both groups there was a postoperative increase in retinal thickness in all observed region with its maximum 1-2 months after surgery, and a subsequent regression of thickening from the third postoperative month onwards. The increase in retinal thickness was statistically significantly greater in the group of diabetics than in the control group of non-diabetics (10).

Measurement of greater macular thickness after cataract surgery may partially be conditioned by an improvement in the quality of the image and partially by morphological changes in the macula, which most probably actually occur. The surgical procedure indicates endogenous synthesis of prostaglandins, which together with other inflammation

mediators breaches the haemato-retinal barrier, and through the infiltration of blood serum from the retinal capillaries and its accumulation in the retina causes the onset of macular edema (11). The development of cystoid macular edema is probably contributed to also by the conservation substance benzalkonium chloride, which is contained in the drops applied in the perioperative period (12). Thickening of the macula in the early postoperative period has also been observed following extraction of a clear lens for reasons of refraction, in which the influence of a turbid lens on the preoperative OCT examination was not a factor (13).

Similarly there are a range of studies which have indicated thickening of the RNLF following cataract surgery. El-Ashry et al. in their study determined whether RNFL thickness measured using OCT changes following cataract surgery. The values of RNFL thickness before and after surgery were statistically significantly different, after surgery there was an increase in RNFL thickness from  $84.9 \pm 16.5 \mu\text{m}$  to  $93.0 \pm 17.6 \mu\text{m}$  (14). A study by the authors Wu et al. determined a correlation between the quality of the OCT scan and measured RNFL thickness. The authors came to the conclusion that in both groups scans with a higher signal were associated with greater RNFL thickness. Also the variability of the strength of the signal upon repeated measurements correlated positively with RNFL thickness. It therefore appears that the removal

of a turbid lens and improvement of the quality of the scan in general leads to an increased in measured RNFL thickness (15). The aim of a study by Koka et al. was to model the influence of cataract on quality of imaging and RNFL thickness upon the use of an SD-OCT instrument. SD-OCT images were recorded using two different instruments before and after cataract surgery. They were subsequently compared against one another and with healthy subjects in whom an effect of cataract was simulated using special filters. The quality of the OCT images improved significantly following cataract surgery in both groups ( $p < 0.001$ ), and in both groups there was also a significant increase in RNFL thickness ( $p < 0.001$ ). Measurement upon the use of special filters demonstrated a linear relationship between induced opacity of the filter and RNFL thickness. The authors of this study are of the opinion that approximately one third of the postoperative increase in RNFL thickness can be explained precisely by the change in the transparency of the optic media. A reduction in the quality of the OCT image may conversely cause an underestimation of the measured RNFL thickness, and may have an influence on determining the diagnosis and evaluating the progression of glaucoma using OCT. On the basis of these observations the stipulation of a new baseline is recommended for further observation of RNFL thickness in patients with glaucoma (16).

A factor that could theoretically influence the quality of OCT examination following cataract surgery and thereby also the values of macular and RNFL thickness is the presence of a colour filter implanted in the intraocular lens. However, in our

study a blue filter in the IOL had no influence on the reproducibility of OCT measurement of macular or RNFL thickness. The same conclusion was reached by Kim et al., who observed the influence of a blue light filter in the IOL on the measurement of peripapillary RNFL thickness using SD-OCT. The patients were divided into two groups according to the type of implanted IOL. Following cataract surgery they recorded a significant increase in RNFL thickness in all quadrants of the disc of the optic nerve with the exception of the temporal quadrant in all patients in both the observed groups, nevertheless no significant difference was found between the groups with different types of IOL. According to the authors the factor influencing the differences in the determined macular and RNFL thickness was not the type of IOL but the strength of the signal, which increased in both groups after cataract surgery (17).

## CONCLUSION

Reproducibility of OCT improved significantly following cataract surgery. At the same time an increase in the thickness of the macula and retinal nerve fibre layer was determined, in particular one month after surgery. It is probable that retinal thickening is partially caused by the better quality and precision of OCT examination following the removal of the turbid lens, and not only due to the change in the anatomical relations on the retina. In patients with glaucoma we recommend the stipulation of a new baseline following cataract surgery in order to observe the thickness of the retinal nerve fibre layer.

## LITERATURE

- Huang D, Swanson EA, Lin CP, et al. Optical coherence tomography. *Science*, 1991; 254(5035): 1178–1181.
- Schuman JS, Hee MR, Arya AV, et al. Optical coherence tomography: a new tool for glaucoma diagnosis. *Curr Opin Ophthalmol*, 1995; 6(2): 89–95.
- Nassif N, Cense B, Park BH, et al. In vivo human retinal imaging by ultra-high-speed spectral domain optical coherence tomography. *Opt Lett*, 2004; 29(5): 480–482.
- Wojtkowski M, Bajraszewski T, Gorczyńska I, et al. Ophthalmic imaging by spectral optical coherence tomography. *Am J Ophthalmol*. 2004; 138(3): 412–419.
- van Velthoven ME, Faber DJ, Verbraak FD, van Leeuwen TG, de Smet MD. Recent developments in optical coherence tomography for imaging the retina. *Prog Retin Eye Res*, 2007; 26(1): 57–77.
- Uživatelský manuál RTVue-100 v 4.0.
- Garcia-Martin E, Pueyo V, Pinilla I, Ara JR, Martin J, Fernandez J. Fourier-domain OCT in multiple sclerosis patients: reproducibility and ability to detect retinal nerve fiber layer atrophy. *Invest Ophthalmol Vis Sci*, 2011; 52(7): 4124–4131.
- Bambo MP, Garcia-Martin E, Otin S, et al. Influence of cataract surgery on repeatability and measurements of spectral domain optical coherence tomography. *Br J Ophthalmol*, 2014; 98(1): 52–58.
- Cagini C, Fiore T, Iaccheri B, Piccinelli F, Ricci MA, Fruttini D. Macular thickness measured by optical coherence tomography in a healthy population before and after uncomplicated cataract phacoemulsification surgery. *Curr Eye Res*, 2009; 34(12): 1036–1041.
- Jurečka T, Bátková Z, Ventruba J, Synek S. Makulární edém po operaci katarakty u diabetiků bez diabetické retinopatie. *Čes a Slov Oftal*, 2007; 63(4): 274–284.
- Miyake K, Ibaraki N. Prostaglandins and Cystoid Macular Edema. *Survey of Ophthalmology*. 2002; 47, Supplement 1(0): S203–S218.
- Miyake K, Ibaraki N, Goto Y, et al. ESCRS Binkhorst lecture 2002: Pseudophakic preservative maculopathy. *J Cataract Refract Surg*, 2003; 29(9): 1800–1810.
- Skorkovská Š, Ventruba J. Hodnocení makulárních změn po refrakční výměně čočky. *Sborník abstrakt, 12. mezinárodní kongres České společnosti refrakční a kataraktové chirurgie*, 23.-24.5 2014, Ostrava, ISBN 978-80-87735-12-1.
- El-Ashry M, Appaswamy S, Deokule S, Pagliarini S. The effect of phacoemulsification cataract surgery on the measurement of retinal nerve fiber layer thickness using optical coherence tomography. *Curr Eye Res*, 2006; 31(5): 409–413.
- Wu Z, Huang J, Dustin L, Sadda SR. Signal strength is an important determinant of accuracy of nerve fiber layer thickness measurement by optical coherence tomography. *J Glaucoma*, 2009; 18(3): 213–216.
- Kok PH, van den Berg TJ, van Dijk HW, et al. The relationship between the optical density of cataract and its influence on retinal nerve fibre layer thickness measured with spectral domain optical coherence tomography. *Acta Ophthalmol*, 2013; 91(5): 418–424.
- Kim JH, Kim NR, Lee ES, Rho S, Kang SY, Kim CY. Influence of blue light-filtering intraocular lenses on retinal nerve fiber layer measurements by spectral-domain optical coherence tomography. *Curr Eye Res*, 2011; 36(10): 937–942.