

EFFECT OF BASELINE CENTRAL RETINAL THICKNESS ON THE RESULTS OF TREATMENT OF DIABETIC MACULAR OEDEMA WITH AFLIBERCEPT: REAL-LIFE EVIDENCE IN THE CZECH REPUBLIC

Němčanský J.¹, Stěpanov A.², Veith M.³, Koubek M.¹, Kopecký A.¹, Němčanská S.¹, Beran D.², Studnička J.²

¹Department of Ophthalmology, University Hospital Ostrava, Faculty of Medicine, Ostrava University, Ostrava, Czech Republic

²Department of Ophthalmology, University Hospital Hradec Králové, Faculty of Medicine, Charles University in Hradec Králové, Hradec Králové, Czech Republic

³Department of Ophthalmology, University Hospital Královské Vinohrady, Third Faculty of Medicine, Charles University, Prague, Czech Republic

The authors of the manuscript declare that the origin and topic of the professional work and its publication are not in conflict of interest and are not supported by any pharmaceutical company. The work was not assigned to another journal or published elsewhere.

Received: 5 November 2021

Accepted: 4 January 2022

Available on-line: 21 March 2022



First author: MUDr. Jan Němčanský, Ph.D., MBA

Corresponding author:
MUDr. Alexandr Stěpanov, Ph.D.,
MBA, FEBO

Oční klinika FN a LF UK v Hradci
Králové

Sokolská 581

500 05 Hradec Králové

E-mail: stepanov.doctor@gmail.com

SUMMARY

Aim: Presentation of the 1-year results of aflibercept treatment in patients suffering from diabetic macular edema (DME) and comparison of the response to treatment of patients with different baseline central retinal thickness (CRT).

Methods: This was a multicentre, retrospective observational study of a series of cases. Patients with DME were treated in a fixed regimen (5 injections at 1-monthly intervals and then injections at 2-monthly intervals). The period of follow-up was 12 months. The development of best corrected visual acuity (BCVA) and CRT was evaluated. Measurements were performed prior to the commencement of treatment and then after 4, 6, 8, 10, and 12 months.

Results: The therapeutically naive group consisted of 82 eyes of 79 patients. The total cohort of patients was divided into 3 groups according to the baseline values of CRT. The first group was composed of 28 eyes with baseline CRT < 450 µm (34.1%), the second included 25 eyes with CRT in the range of 450–550 µm (30.5%), and the third group consisted of 29 eyes with baseline CRT > 550 µm (35.4%). The average baseline BCVA and SD in the first group was 66 ± 7.1 letters ETDRS optotypes, and then 70 ± 7 letters, 69.6 ± 7.3 letters, and 71.3 ± 7 letters at the follow-ups after 4, 8, and 12 months. The average baseline value of CRT and SD in the first group was 379 ± 48.6 µm, and then 337.1 ± 76.5 µm, 320.2 ± 74.1 µm, and 315.1 ± 62.2 µm after 4, 8, and 12 months. The average baseline BCVA and SD in the second group was 64.1 ± 9.7 ETDRS letters, and then 66.9 ± 10 letters, 70 ± 9.9 letters, and 70.5 ± 11.5 letters after 4, 8, and 12 months. The average baseline value of CRT and SD in the second group was 497.4 ± 76.4 µm, and then 376.5 ± 106.1 µm, 360.8 ± 70 µm, and 351.3 ± 91.3 µm after 4, 8, and 12 months. In the third group, the average baseline value of BCVA and SD was 59.7 ± 10.4 ETDRS letters, and then 65 ± 10.6 letters, 64.8 ± 9.6 letters, and 67 ± 10 letters after 4, 8, and 12 months. The average baseline value of CRT and SD in the third group was 639.4 ± 79.6 µm, and then 396.7 ± 147.1 µm, 416.9 ± 139.8 µm, and 368.5 ± 109.9 µm after 4, 8, and 12 months. All these changes were statistically significant (p < 0.05).

Conclusion: Aflibercept treatment in a fixed regimen in patients suffering from DME results in a statistically significant improvement in BCVA and a decrease in CRT in the first year of treatment. Patients with a higher baseline CRT showed the best anatomical and functional results of the 1-year treatment with aflibercept.

Key words: anti-VEGF therapy, aflibercept, diabetic macular edema, real-life practice

Čes. a slov. Oftal., 78, 2022, No. 2, p. 64–70

INTRODUCTION

Diabetic retinopathy and diabetic macular oedema (DME) rank among the most frequent causes of grave loss of vision in patients of productive age. Considering the large number of diabetic patients in the population, it is a disease with a significant impact on public health [1–4]. For several decades, the gold standard for treatment of DME has been laser photocoagulation of the retina [5,6]. Despite progress in the construction of lasers, this type of treatment mostly only stabilises visual function [7]. The therapeutic effect on DME of intravitreally administered steroids has also been demonstrated [8]. However, it is only with the development of antibodies against vascular endothelial growth factor (anti-VEGF) that there has been a marked change in the paradigm of treatment of DME, leading to vision improvement for patients [9]. Today, anti-VEGF applied into the vitreous body represents the first-choice pharmacotherapy for DME, and several clinical studies have demonstrated its significant effect on both the best corrected visual acuity (BCVA) and the central retinal thickness (CRT). The drugs approved for intraocular administration are primarily ranibizumab (Lucentis; Genentech USA Inc., San Francisco, CA, USA) [10,11] and aflibercept (Eylea; Regeneron Pharmaceutical Inc., Tarrytown, NY, USA, and Bayer Healthcare, Berlin, Germany) [12]. Despite the fact that in some countries it is used to treat retinal diseases, bevacizumab (Avastin; Genentech USA Inc., San Francisco, CA, USA) has not been approved for intraocular administration [13].

Ranibizumab was used at the beginning, primarily in a fixed therapeutic regimen at 1-monthly intervals, and later also in a reactive regimen *pro re nata* (PRN), and most recently in the proactive regimen Treat and Extend (T&E). With such regimens, it is necessary to monitor and treat the patients with ranibizumab at short, often 1-monthly intervals. In such cases, there exists the risk of the diminished compliance of patients, and further it causes high socioeconomic costs for healthcare systems and society [14]. The main problem identified in the course of therapy was the burden of clinical visits at 1-monthly intervals, for which most patients needed to be accompanied [15].

Aflibercept, besides blocking all isoforms of VEGF, also blocks placental growth factor. In addition, its structure confers a higher affinity to VEGF and delivers a longer-term effect, both *in vitro* [16] and *in vivo* [17]. Thanks to this, aflibercept possesses very good effectivity, while keeping the load bearable for patients and medical personnel, even in the fixed dosing regimen, when, after the 5-month satiating dosage, the original 1-monthly therapeutic intervals are extended to 2 months.

This retrospective study aimed to chart the progress of BCVA and CRT in what is known as naive DME patients (those not previously treated with anti-VEGF preparations), divided into three groups according to their baseline CRT values. Intravitreal aflibercept therapy was performed in a fixed regimen for a period of 12 months.

MATERIAL AND METHODOLOGY

This was a multicentre, retrospective observational study of a series of cases, comprising patients from real-life clinical practice during the period from March 2016 to August 2019 at the University Hospital Ostrava, University Hospital Hradec Králové, and University Hospital Královské Vinohrady, Prague.

The study included 82 eyes of 79 patients who fulfilled the inclusion criteria (both eyes were treated in 3 patients). The characterisation of the cohort is presented in Table 1. They were patients with type 1 or type 2 diabetes mellitus with manifested hitherto untreated DME. The inclusion criteria were BCVA within the range of 40–75 letters of ETDRS (Early Treatment Diabetic Retinopathy Study) optotypes in the affected eye (20/32–20/160 in Snellen optotypes), and CRT \geq 300 μ m. The HbA1c level of the patients was up to 70 mmol/mol, and the level of total cholesterol up to 4.8 mmol/L. Other criteria for inclusion were: administration of aflibercept in a proactive fixed regimen, i.e. therapy commencing with the administration of 5 doses at 1-monthly intervals, followed by further doses every 2 months during a 12-month monitoring period. One exception to the dosing regimen was tolerated, i.e. the minimum number of injections was 7. Patients with another possible cause of decreased BCVA (e.g. progression of cataract, other pathologies of the anterior or posterior segment of the eye, etc.) were excluded. The other exclusion criteria were status post-ictus, decompensated arterial hypertension with blood pressure above 140/90 mmHg, diabetic nephropathy with serum creatinine level above 180 μ mol/l, duration of DME for longer than 2 years, and a high-risk form of proliferative diabetic retinopathy (PDR).

The total cohort of patients was divided into 3 groups according to the baseline values of CRT. The first group consisted of 28 eyes with baseline CRT < 450 μ m (34.1%), the second group included 25 eyes with CRT in the range of 450–550 μ m (30.5%), and the third group was composed of 29 eyes with baseline CRT > 550 μ m (35.4%). The average age of patients in the whole cohort was 67.3 years (range 43–87); the average age of the first group of patients was 69.3 years (range 51–85), of whom 13 were female (46.4%); that of the second group was 65.5 years (range 43–87), of whom 9 were female (36%); and of the third group average age was 66.9 years (range 51–86), of whom 15 were female (51.7%). All patients were treated with aflibercept during the 1-year monitoring period; altogether 7.7 ± 1.2 injections (minimally 7) were administered, 7.8 ± 1.5 in the first group, 8.6 ± 1.3 in the second group, and 7.5 ± 0.9 in the third group.

Intravitreal injections were administered to all patients under aseptic conditions in an operating room, according to established standards of healthcare valid at the individual hospital facilities.

While monitoring, all patients underwent a BCVA

Table 1. Baseline characteristics of patient cohorts

| | Total patient cohorts (n = 79) | Group 1 CRT < 450 µm | Group 2 CRT 450–550 µm | Group 3 CRT > 550 µm |
|------------------------------------------------------------|-------------------------------------------|----------------------------------------|-----------------------------------|------------------------------------------|
| Number of eyes, n (%) | 82 (100 %) | 28 (34,1 %) | 25 (30,5 %) | 29 (35,4 %) |
| Age (years) min–max | 67,3 43–87 | 69,3 51–85 | 65,5 43–87 | 66,9 51–86 |
| Females, n (%) | 37 (46,8 %) | 13 (46,4 %) | 9 (36 %) | 15 (36 %) |
| Diabetes, n (%) Type I Type II | 2 (2,5 %) 77 (97,5 %) | 1 (3,4 %) 27 (96,6 %) | 1 (4 %) 24 (96 %) | 0 29 (100 %) |
| Treatment of DME, n (%) Insulin PAD Insulin + PAD | 39 (47,6 %) 30 (36,6 %) 13 (15,8 %) | 14 (50 %) 11 (39,3 %) 3 (10,7 %) | 13 (52 %) 8 (32 %) 4 (16 %) | 12 (41,4 %) 11 (37,9 %) 6 (20,7 %) |
| Duration of DM (years) | 10,6 | 11,9 | 10,3 | 9,4 |
| HbA1c (mmol/mol) | 53,6 | 54,5 | 53,4 | 52,8 |
| Cholesterol (mmol/l) | 4,2 | 4,3 | 4,0 | 4,2 |
| Creatinine (mmol/l) | 84,2 | 81,8 | 87,1 | 83,5 |
| Duration of DME (months) | 14,0 | 13,2 | 13,9 | 15,1 |
| BCVA ±SD (letters of ETDRS optotypes) | 63,4 ±9,5 | 66,0 ±7,1 | 64,1 ±9,7 | 59,7 ±10,4 |
| CRT ±SD (µm) | 499,4 ±125,6 | 379,0 ±48,6 | 497,4 ±76,4 | 639,4 ±79,6 |

CRT – central retinal thickness, DME – diabetic macular edema, BCVA – best corrected visual acuity, DM – diabetes mellitus, SD – standard deviation

examination on ETDRS optotypes, an examination by slit lamp with biomicroscopy of the fundus under artificial mydriasis after administration of 0.5% tropicamide, and optical coherence tomography (OCT) using an OCT Cirrus 4000 device (ZEISS, Oberkochen, Germany). At the Faculty Hospital in Ostrava, examinations were performed using a Spectralis OCT device (Heidelberg Engineering GmbH, Heidelberg, Germany) with automatic analysis of the thickness of the retina. CRT was defined as the distance between the internal limiting membrane and RPE in the fovea. To be able to compare the results from the Cirrus and Spectralis devices, the values of CRT measured by the Spectralis OCT instrument were then recalculated, using the equation published by Krebs et al. [18]. These examinations were performed prior to the beginning of treatment and at months 4, 6, 8, 10, and 12. Prior to the administration of intravitreal injections, all patients signed an informed consent. The protocol of the study observed the principles of the Helsinki Declaration.

Statistical analysis

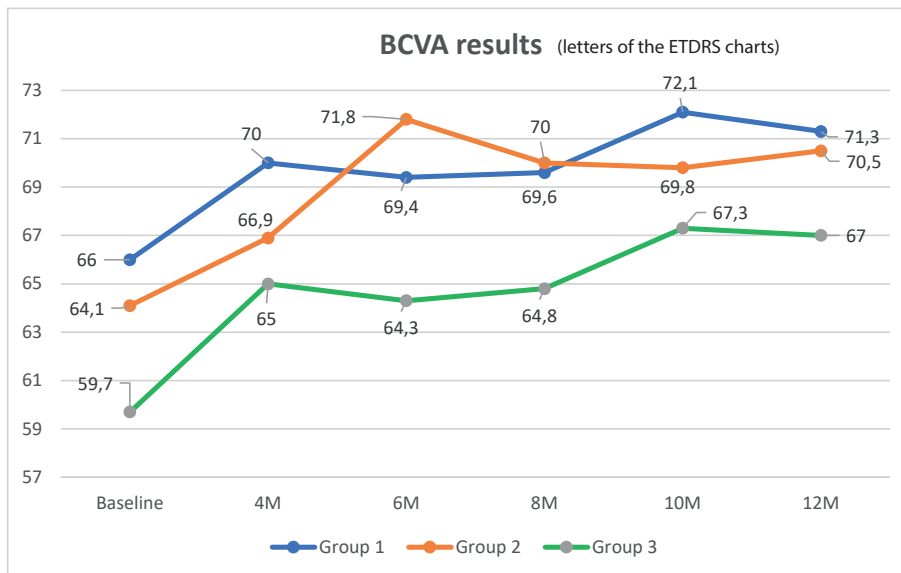
Statistical analysis was carried out using IBM SPSS Statistics 23 software. Quantitative data are presented as the mean and interval. BCVA and CRT data were processed by the Kolmogorov-Smirnov normality test, the hypothesis of equality being refused. The changes in BCVA and

CRT measured at the beginning and at 4, 6, 8, 10, and 12 months were evaluated using the Friedman test. The subsequent multiple comparisons were carried out using the paired Wilcoxon test, modified by the Bonferroni correction. Statistical significance was defined as $p < 0.05$.

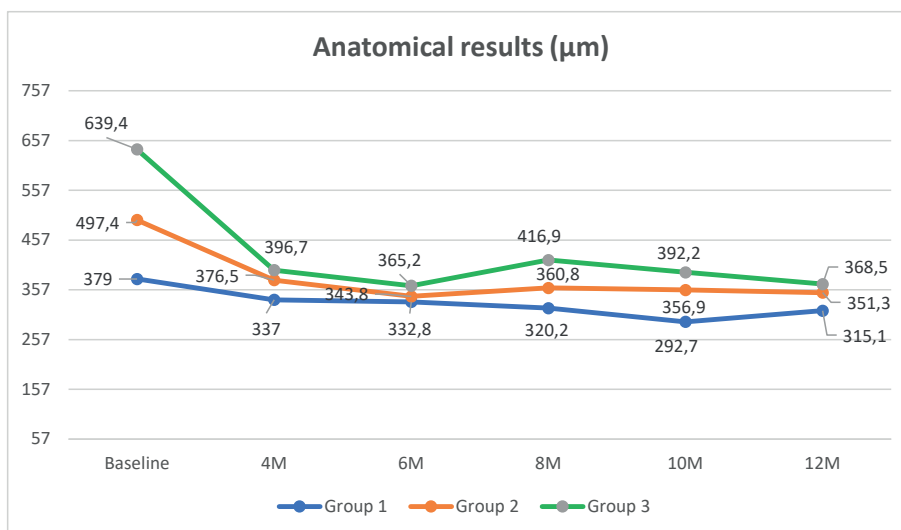
RESULTS

Analysis of visual acuity

The baseline value of BCVA and SD was 63.4 ± 9.5 letters of ETDRS optotypes for the whole cohort, of which 66 ± 7.1 letters were in patients in the first group, 64.1 ± 9.7 letters in the second group, and 59.7 ± 10.4 letters in the third group. The values of BCVA and their changes are shown in Graph 1. BCVA at the end of the 1-year follow-up period was 69.7 ± 9.9 letters of ETDRS optotypes for the whole cohort, 71.3 ± 7 letters in patients in the first group, 70.5 ± 11.5 letters in the second group, and 67 ± 10 letters in the third group. Changes from the baseline values were statistically significant in the whole follow-up period ($p < 0.05$). The most significant change was observed after 6 months of aflibercept therapy in the second group ($+7.7$ letters of ETDRS optotypes from the initial values ($p < 0.05$)), Graph 3. In patients from the first and third groups, the most significant change in BCVA was observed at the control in month 10 of the monitoring period ($+6.1$ and $+7.3$ letters of ETDRS optotypes from the initial values ($p < 0.05$)), Graph 3.



Graph 1. Functional outcomes over time for eyes with diabetic macular oedema with different baseline central retinal thickness (CRT). All groups showed improvement of the best corrected visual acuity from baseline to final 12-month follow-up; however, the group with CRT > 550 µm showed the greatest letter gain
BCVA – best corrected visual acuity, ETDRS – Early Treatment Diabetic Retinopathy Study, M – month



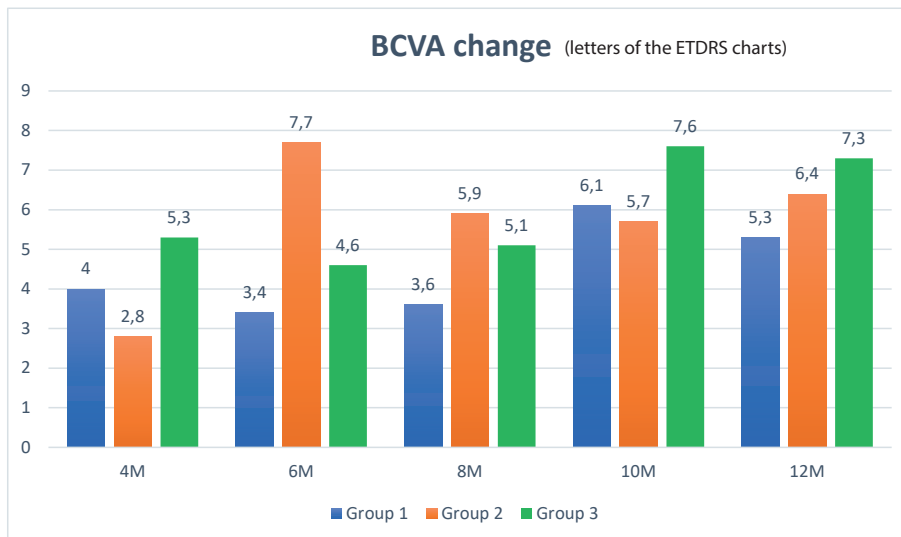
Graph 2. Anatomical outcomes over time for eyes with diabetic macular oedema with different baseline central retinal thickness (CRT). All groups showed a significant decrease in CRT from baseline to final 12-month follow-up
M – month

At the end of the 1-year aflibercept treatment, a benefit of ≥ 15 letters of ETDRS optotypes was observed in 24.4% (n = 20) of the whole cohort of patients; in the first group, this benefit was observed in 21.4% (n = 6), in the second, 32% (n = 8), and in the third group, in 20.7% of patients (n = 6) (p < 0.05).

Anatomical results

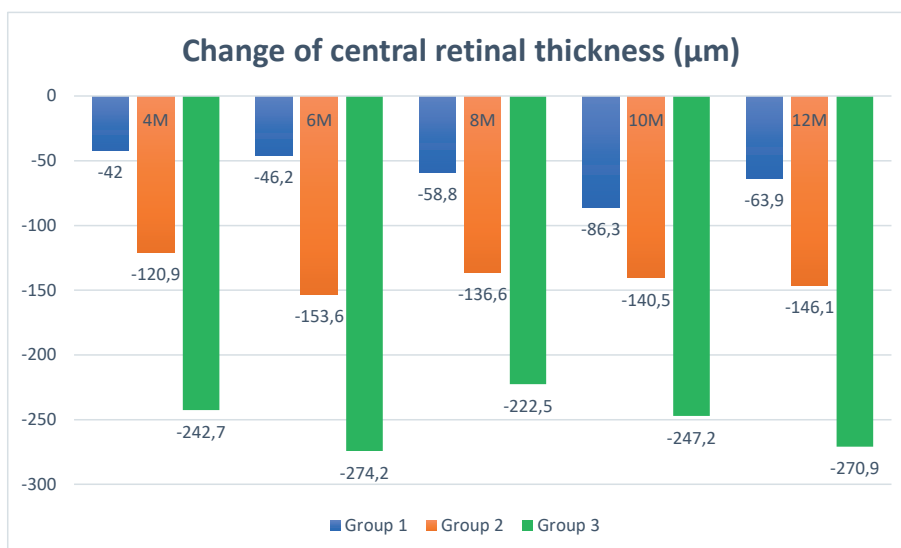
The average baseline value of CRT and SD was 499.4 ± 125.6 µm for the whole cohort, with an average of 379

± 48.6 µm for patients in the first group, 497.4 ± 76.4 µm in the second group, and 639.4 ± 79.6 µm in the third group. The baseline values of CRT and their changes are presented in Graph 2. CRT and SD at the end of the 1-year monitoring period was 344.3 ± 91.9 µm for the whole cohort, specifically 315.1 ± 62.2 µm for patients in the first group, 351.3 ± 91.3 in the second group, and 368.5 ± 109.9 µm in the third group (p < 0.05). The most significant changes were observed at the check-up after 6 months of therapy in patients in the third group,



Graph 3. The mean change in letters of the ETDRS chart from baseline for three groups with different baseline central retinal thickness during the first year of aflibercept treatment

BCVA – best corrected visual acuity, ETDRS – Early Treatment Diabetic Retinopathy Study, M – month



Graph 4. The mean change of central retinal thickness (CRT) in micrometres from baseline for three groups with different baseline CRT during the first year of aflibercept treatment

M – month

where CRT decreased by $-274.2 \mu\text{m}$, and in the second group, with a change of $-153.6 \mu\text{m}$ from the initial values (Graph 4). In the first group, the greatest change $-86.3 \mu\text{m}$ appeared at the check-up at month 10 (Graph 4). The decrease in CRT was statistically significant in all groups ($p < 0.05$). At the end of the monitored period, macular edema was still present in 51.2% of all patients ($n = 42$), of whom 46.4% were in the first group ($n = 13$), 48% in the second group ($n = 12$), and 58.6% in the third group ($n = 17$).

During the course of the monitoring period, no signi-

ficant ocular or systemic undesirable effects of therapy were observed.

DISCUSSION

The present retrospective study evaluated the functional and anatomical results of aflibercept therapy administered in a fixed regimen to therapeutically naive eyes with DME in real-life clinical practice in the Czech Republic. The study included a relatively large cohort of eyes ($n = 82$), and the total cohort was subsequently divided into

3 groups according to the baseline value of CRT.

Comparison of efficacy and safety in eyes with DME treated with either aflibercept 2 mg, bevacizumab 1.25 mg, or ranibizumab 0.3 mg was assayed within protocol T of the DRCR.net study (Diabetic Retinopathy Clinical Research Network) [13]. In the present cohort of patients, the average improvement of BCVA in the total cohort of patients after 1 year of therapy was +6.3 letters of ETDRS optotypes, which is 7 letters less than within protocol T of the DRCR.net study [13]. This difference is explained by the better baseline BCVA in our cohort (by 7.2 letters), the smaller number of injections of aflibercept over the 1 year of treatment (1.3 fewer injections), the use of supplementing relief laser therapy for DME in the DRCR.net study (altogether 37% of eyes were treated), and the conditions of therapy in real-life clinical practice. The decrease in CRT in our study by 155.1 μm , despite a smaller number of aflibercept injections, is comparable with the decrease in CRT by 169 μm in the DRCR.net study.

After the 1-year aflibercept therapy, BCVA in the present cohort was improved by 4.4 letters of ETDRS optotypes less than in the VISTA-DME and VIVID-DME studies [12]. This difference is explained by a better baseline BCVA in our cohort (by 4 letters than in the VISTA-DME study and by 4.6 letters than in the VIVID-DME study), a smaller number of aflibercept administrations (by 0.7 injection less than in the VISTA-DME study, and by 1 injection less than in the VIVID-DME study), and by the conditions of treatment in real-life clinical practice. The change in CRT at the end of the 1-year follow-up period in the present study is comparable with the anatomical results of the therapy in the VISTA-DME and VIVID-DME studies (155.1 μm versus 183.1 and 182.4 μm , respectively).

The post hoc analysis of the VIVID-DME and VISTA-DME studies focused on the effect of the baseline CRT on the resulting BCVA [19]. The whole cohort of patients was divided into 2 groups, those with CRT < 400 μm and those with CRT \geq 400 μm . The group of patients with CRT < 400 μm , treated in the regimen of 2 mg aflibercept every 8 weeks (2q8), included 78 patients with an average baseline BCVA of 63 letters of ETDRS optotypes and average CRT 337 μm . After 1 year of treatment, an improvement in BCVA on average by 10.5 letters and a decrease in CRT by 191.2 μm were recorded. An improvement in BCVA of \geq 15 letters of ETDRS optotypes was demonstrated in 21.8% of patients. The group of patients with CRT \geq 400 μm consisted of 208 patients, where the average BCVA was 57.7 letters of ETDRS optotypes, and the average value of CRT was 551.9 μm . After 1 year of treatment, an improvement in BCVA on average by 10.7 letters and a decrease in CRT by 188 μm were recorded in this group. An improvement of BCVA by \geq 15 letters of ETDRS optotypes was demonstrated in 36.1% of patients. The results after the 1-year treatment with aflibercept showed no statistically significant difference between the groups ($p = 0.11$).

The total cohort of patients in our study was divided according to the baseline values of CRT into 3 groups

(< 450 μm , 450–550 μm , and > 550 μm). Identically to Midena et al., we have observed no statistically significant difference in BCVA improvement after 1 year of aflibercept treatment between the groups. Nevertheless, we consider the division into 3 groups to be more clearly arranged and beneficial than the division into 2 groups. Unlike the Midena methodology, our division yielded more balanced numbers of patients in the individual groups. The results of a 1-year treatment of DME with aflibercept in routine clinical practice were published by Lukic et al. from Moorfield [20], and Korobelnik et al., who presented the conclusion of the French APOLLON study [21].

The cohort of patients in the study of Lukic et al. consisted of 99 eyes, with an average initial BCVA of 59.7 letters of ETDRS optotypes and an average CRT of 431 μm [20]. After an introductory 5 of 1-monthly aflibercept administrations, the treatment continued in the PRN regimen. In the course of the monitoring period, 6.9 injections of aflibercept were administered. After 1 year of treatment, improvement in BCVA was on average by 9.9 letters of ETDRS optotypes, and CRT decreased by 128 μm . In addition, the Lukic study carried out a sub-analysis of anatomical results of treatment, where the total cohort of patients was divided into 2 groups according to the baseline values of CRT 400–499 μm (73 eyes) and CRT \geq 500 μm (26 eyes). The average change in CRT in the group with the lower baseline CRT was 86 μm at the end of the 1-year monitoring period, whereas in the group with the higher baseline CRT, this change was 265 μm .

The lesser improvement of BCVA by 3.6 letters of ETDRS optotypes in our study in comparison with that of Lukic et al. can be explained by a better baseline BCVA in our cohort (by 3.7 letters). The division of the whole cohort into 3 groups according to the values of CRT made it possible to better evaluate the anatomical results of therapy than with a division into 2 groups.

The APOLLON study included a cohort of 77 hitherto untreated eyes with DME, with an average baseline BCVA of 62.7 letters of ETDRS optotypes and an average CRT of 439 μm . Identically to the study of Lukic et al., after the introductory 5 months' administration of aflibercept, therapy continued under a PRN regimen. In the course of the monitoring period, on average of 7.6 injections of aflibercept were administered. After 1 year of therapy, an improvement in BCVA on average by 8.4 letters of ETDRS optotypes and a decrease in CRT by 129.5 μm were observed. BCVA improvement by \geq 15 letters of ETDRS optotypes was demonstrated in 35% of patients. The results of therapy in our total cohort are comparable with those in the APOLLON study.

Our study, according to the information available to us, is the first study to evaluate the 1-year functional and anatomical results of aflibercept therapy in routine clinical practice, in patients with DME divided into 3 groups according to the baseline values of CRT. Patients with a higher baseline CRT showed the best anatomical and functional results of 1 year's aflibercept therapy.

These results can be explained by a reserve for a greater gain of letters of ETDRS optotypes in the lowest baseline values, and a greater decrease in CRT in the group with CRT > 550 µm.

The strong aspects of our study include a multicentre data collection design from three major university centres. The limitations of our study are the observational character and the relatively small size of the sample, compared to the larger clinical studies.

CONCLUSION

The manuscript presents 1 year's results from real-life practice in hitherto untreated patients suffering from DME, divided into 3 groups according to the baseline value of CRT, and treated with aflibercept in a fixed regimen. Based on the present authors' experience, patients with a higher baseline CRT have shown the best anatomical and functional results of 1 year of aflibercept therapy

REFERENCES

1. Yau JW, Rogers SL, Kawasaki R, et al. Global prevalence and major risk factors of diabetic retinopathy. *Diabetes Care*. 2012;35(3):556-564.
2. Kim EJ, Lin WV, Rodriguez SM, Chen A, Loya A, Weng CY. Treatment of Diabetic Macular Edema. *Curr Diab Rep*. 2019;19(9):68.
3. Amoaku WM, Ghanchi F, Bailey C, et al. Diabetic retinopathy and diabetic macular oedema pathways and management: UK Consensus Working Group. *Eye (Lond)*. 2020;34(Suppl 1):1-51.
4. Sabanayagam C, Yip W, Ting DS, Tan G, Wong TY. Ten Emerging Trends in the Epidemiology of Diabetic Retinopathy. *Ophthalmic Epidemiol*. 2016;23(4):209-222.
5. Early Treatment Diabetic Retinopathy Study research group. Photocoagulation for diabetic macular edema. Early Treatment Diabetic Retinopathy Study report number 1. *Arch Ophthalmol*. 1985;103(12):1796-1806.
6. Early Treatment Diabetic Retinopathy Study Research Group. Treatment techniques and clinical guidelines for photocoagulation of diabetic macular edema. Early Treatment Diabetic Retinopathy Study Report Number 2. *Ophthalmology*. 1987;94(7):761-774.
7. Nemcansky J, Stepanov A, Nemcanska S, Masek P, Langrova H, Studnicka J. Single session of pattern scanning laser versus multiple sessions of conventional laser for panretinal photocoagulation in diabetic retinopathy: Efficacy, safety and painfulness. *PLoS One*. 2019;14(7):e0219282.
8. Beck RW, Edwards AR, Aiello LP, et al. Three-year follow-up of a randomized trial comparing focal/grid photocoagulation and intravitreal triamcinolone for diabetic macular edema. *Arch Ophthalmol*. 2009;127(3):245-251.
9. Schmidt-Erfurth U, Garcia-Arumi J, Bandello F, et al. Guidelines for the Management of Diabetic Macular Edema by the European Society of Retina Specialists (EURETINA). *Ophthalmologica*. 2017;237(4):185-222.
10. Mitchell P, Bandello F, Schmidt-Erfurth U, et al. The RESTORE study: ranibizumab monotherapy or combined with laser versus laser monotherapy for diabetic macular edema. *Ophthalmology*. 2011;118(4):615-625.
11. Nguyen QD, Brown DM, Marcus DM, et al. Ranibizumab for diabetic macular edema: results from 2 phase III randomized trials: RISE and RIDE. *Ophthalmology*. 2012;119(4):789-801.
12. Korobelnik JF, Do DV, Schmidt-Erfurth U, et al. Intravitreal aflibercept for diabetic macular edema. *Ophthalmology*. 2014;121(11):2247-2254.
13. Wells JA, Glassman AR, Ayala AR, et al. Aflibercept, bevacizumab, or ranibizumab for diabetic macular edema. *N Engl J Med*. 2015;372(13):1193-1203.
14. Martin DF, Maguire MG, Ying GS, et al. Ranibizumab and bevacizumab for neovascular age-related macular degeneration. *N Engl J Med*. 2011;364(20):1897-1908.
15. Droege KM, Muether PS, Hermann MM, et al. Adherence to ranibizumab treatment for neovascular age-related macular degeneration in real life. *Graefes Arch Clin Exp Ophthalmol*. 2013;251(5):1281-1284.
16. Papadopoulos N, Martin J, Ruan Q, et al. Binding and neutralization of vascular endothelial growth factor (VEGF) and related ligands by VEGF Trap, ranibizumab and bevacizumab. *Angiogenesis*. 2012;15(2):171-185.
17. Fauser S, Muether PS. Clinical correlation to differences in ranibizumab and aflibercept vascular endothelial growth factor suppression times. *Br J Ophthalmol*. 2016;100(11):1494-1498.
18. Krebs I, Smretschnick E, Moussa S, Brannath W, Womastek I, Binder S. Quality and reproducibility of retinal thickness measurements in two spectral-domain optical coherence tomography machines. *Invest Ophthalmol Vis Sci*. 2011;52(9):6925-6933.
19. Midena E, Gillies M, Katz TA, Metzigg C, Lu C, Ogura Y. Impact of Baseline Central Retinal Thickness on Outcomes in the VIVID-DME and VISTA-DME Studies. *J Ophthalmol*. 2018;3640135
20. Lukic M, Williams G, Shalchi Z, et al. Intravitreal aflibercept for diabetic macular oedema: Moorfields' real-world 12-month visual acuity and anatomical outcomes. *Eur J Ophthalmol*. 2020;30(3):557-562
21. Korobelnik JF, Daien V, Faure C, et al. Real-world outcomes following 12 months of intravitreal aflibercept monotherapy in patients with diabetic macular edema in France: results from the APOLLON study. *Graefes Arch Clin Exp Ophthalmol*. 2020;258(3):521-528.