

# CENTRAL SEROUS CHORIORETINOPATHY. A REVIEW

Myslík Manethová, K.<sup>1,2</sup>

<sup>1</sup> Department of Ophthalmology, Thomayer University Hospital, Prague, Czech Republic

<sup>2</sup> Královské Vinohrady University Hospital and 3<sup>rd</sup> Faculty of Medicine, Charles University Prague, Czech Republic

The author of the study declares that no conflict of interests exists in the compilation, theme and subsequent publication of this professional article, and that it is not supported by any pharmaceuticals company. The study has not been submitted to in any other journal or published elsewhere, with the exception of congress abstracts and recommended procedures.

Received: October 2, 2022

Accepted: April 3, 2023

Available on-line: June 30, 2023



MUDr. Kateřina Myslík Manethová,  
Ph.D., FEBO

Vídeňská 800

140 59 Praha 4 - Krč

E-mail: katerina.manethova@ftn.cz

Central serous chorioretinopathy (CSC) is a disease characterized by serous detachment of the neuroretina, especially in the posterior pole of the eye. It is often accompanied by serous detachment of the retinal pigment epithelium (RPE) and associated with the leakage of fluid into the subretinal space through the defective RPE. CSC most often affects men of working age. The exact pathophysiology of the disease is not completely known. Based on indocyanine green angiography (ICG), which revealed increased permeability of choroidal vessels, and optical coherence tomography (OCT) showing increased choroidal thickness, choroidal vasculopathy is assumed to be the primary cause of CSC. In most cases, CSC has a good prognosis with spontaneous resorption of the subretinal fluid (SRF) and improvement of visual functions. However, in a small percentage of patients the disease progresses to a chronic or recurrent course, and can lead to irreversible functional and anatomical changes of the retina with a final clinical picture of diffuse retinal pigment epitheliopathy (DRPE). The optimal treatment approach for patients with CSC remains controversial. In recent decades, myriad therapeutic approaches have been used in the treatment of chronic forms of CSC (cCSC); these included for example laser photocoagulation, pharmaceutical treatment, standard photodynamic therapy (PDT) or anti-VEGF. In recent years a less destructive method, specifically PDT in reduced dose regimens, either with a reduced dose of verteporfin or the laser beam energy used, has been preferred in the treatment of cCSC. Comparable efficacy and safety has been demonstrated using reduced-dose or reduced-fluence PDT regimens in patients with cCSC, with an improvement in best-corrected visual acuity and reduction of SRF.

**Key words:** central serous chorioretinopathy, retinal degeneration, choroidal neovascularization, multimodal imaging, photodynamic therapy

Čes. a slov. Oftal., 79, 2023, No. x, p. x-x

## INTRODUCTION

Central serous chorioretinopathy (CSC) is a pathology characterized by serous detachment of the neuroretina, especially in the region of the posterior pole of the eye [1]. It is frequently accompanied with serous detachment of the retinal pigment epithelium (RPE) and associated with the leakage of fluid into the subretinal space through the defective RPE. CSC most often affects men of working age [2]. The precise physiopathology of the disease is not entirely known. On the basis of angiographic examination with indocyanine green (ICG), which detected increased permeability of the choroidal vessels [3], and optical coherence tomography (OCT) showing increased choroidal thickness [4], choroidal vasculopathy is considered to be the primary cause of CSC.

In the majority of cases, CSC has a good prognosis, with spontaneous resorption of the subretinal fluid (SRF) and improvement of visual functions. However, in a small per-

centage of patients the pathology progresses to a chronic or recurrent course, and may lead to irreversible anatomical changes of the retina, with a final clinical picture of diffuse retinal pigment epitheliopathy (DRPE) [3].

The optimal therapeutic approach to patients with CSC remains controversial. In recent decades countless therapeutic approaches have been used in the treatment of chronic forms of CSC (cCSC); these have included for example laser photocoagulation [5], pharmaceutical treatment [6,7], standard photodynamic therapy (PDT) [8] or agents acting against vascular endothelial growth factor (anti-VEGF) [9]. In recent years, a less destructive method has been preferred in the treatment of cCSC, specifically PDT in reduced dose regimens (rPDT), whether this concerns a reduced dose of verteporfin or reduced used energy of the laser beam [10–12]. Alkin, Chan and Uetani have demonstrated comparable efficacy and safety in the use of reduced-dose or reduced-fluence PDT in patients with cCSC, in whom an improvement of best co-

rected visual acuity (BCVA) and a reduction of SRF was achieved, without any complications being recorded in the observed cohort [13–15].

No standards exist in the Czech Republic for the treatment of this clinical unit. Because the disease typically affects younger patients of working age with high demands for quality of vision, correct timing and accurate designation of treatment remain an acute challenge, especially in the case of chronic form of CSC. Whereas treatment previously relied exclusively on laser treatment of the retina [16], in recent years more conservative methods have been favored particularly in the treatment of chronic forms of CSC, such as PDT or intravitreal application of antiangiogenic substances [17,18].

## HISTORY

Historically, a pathology of the macula with recurrent serous retinal detachment was first described in 1866 by von Graef, termed recurrent central retinitis [19]. Almost one hundred years later in 1955, Bennet used the term central serous retinopathy, since he believed that the fluid originated from leaking retinal capillaries, and not upon the background of inflammation or angiospasm [20]. In the 1960s, thanks to the introduction of fluorescence angiography into clinical practice, Maumenee determined that the fluid was penetrating beneath the retina through the damaged RPE [21]. Thanks to a further study of the characteristics of fluorescein angiography (FAG) in CSC, in 1967 Gass presented a more detailed view of the pathogenesis of the disease, as well as a clinical picture, and showed that CSC affects both the retina and the choroid. He introduced the new term idiopathic central serous choroidopathy [22]. With regard to the fact that the increased permeability of the choroidal vessels, leading to a leakage of fluid through the damaged RPE and subsequently to detachment of the neurosensory part of the retina, is generally acknowledged to be the cause of the pathology, the current nomenclature favors the term central serous chorioretinopathy [23].

In recent years, “multimodal imaging” has enjoyed a considerable expansion in the examination of chorioretinal pathologies. Thanks to modern examination techniques (“enhanced depth imaging” OCT, “swept-source” OCT, OCT-angiography), alongside polypoidal choroidal vasculopathy, pachychoroid neovasculopathy and pachychoroid pigment epitheliopathy, CSC is newly classified among “pachychoroid” diseases, a key feature of which is increased choroidal thickness (the Greek prefix “pachy” means thick) [24]. Another typical characteristic of CSC is dilation of the Haller’s layer of the choroidal blood vessels and compression of the choriocapillaris located above these vessels [25].

## SYMPTOMS, DEMOGRAPHICS, RISK FACTORS

The pathology is characterized first of all by a slight blurring of vision, which is followed by varying degrees

of deterioration of central visual acuity (VA) (6/6–6/60), micropsias, deformation of image, hypermetropia, a reduction of contrast sensitivity, change of color perception, and varying degrees of central scotoma. The symptoms tend to be mostly temporary and are often unilateral, although bilateral affliction is also relatively frequent [23]. It is not rare for CSC to have an asymptomatic course, or for serous retinal detachment to be identified entirely by chance during the treatment of a contralateral affliction of the eye [25]. The incidence of CSC varies according to different ethnic groups. A higher incidence has been recorded among Asians and whites in comparison with the black population. A bilateral and multifocal character of the pathology is also described more often among Asians [26]; high ablations of the RPE and neuroretina, which are more common in the Asian population, may be mistaken for Harada’s disease [27]. Men aged between 30 and 50 are predominantly affected (the average incidence of the disease in men and women is within a ratio of 8–9 : 1) [28,29]. In his study, Spaide stated the average age of patients with CSC at 51 years, although at the same time he conceded that in older patients, in whom the disease is more likely to be manifested in diffuse disintegration of the RPE or the presence of serous choroidal neovascularization (CNV), the initial signs of the disease may have appeared several years before the determination of the diagnosis [3]. Age-related macular degeneration (ARMD) associated with CNV may in some cases resemble CSC, and as a result in patients aged over 50 years it is necessary to exclude ARMD [30]. Despite the fact that the pathology is of an idiopathic character, it is known that CSC is generally more frequently associated with states of endogenous hypercortisolism (e.g. in Cushing’s syndrome, pregnancy) and in long-term systemic therapy with glucocorticoids (treatment of multiple sclerosis, asthma, Crohn’s disease), in which increased adrenergic stimulation of certain tissues takes place, influencing changes of blood pressure and tissue homeostasis [31–33]. In addition, a higher incidence of CSC has been described in women during the course of pregnancy (a condition with an increased level of freely circulating endogenous cortisol), in patients following an organ transplant with chronic use of immunosuppressants and corticoid therapy, or as a consequence of protracted stress burden [32,34,35]. Relatively substantial significance is attributed to psychosocial aspects. In 1927, Horniker was the first to identify a correlation between psychological agitation and an increased risk of the development of CSC; he referred to the pathology itself as retinitis centralis angioneurotica [36]. Nonetheless, it was not until 1986 that Yannuzzi definitively demonstrated an association between CSC and the type “A” personality (i.e. coronary personality with a tendency towards early onset of cardiovascular disease). This association is probably due to the increased level of catecholamines in circulation [37]. In Czech ophthalmological slang, CSC is referred to as the “managers’ disease”. According to other literary sources an increased incidence of the pathology has been

described also in patients using phosphodiesterase type 5 inhibitors for erectile dysfunction [38], sympathomimetic substances such as pseudoephedrine, oxymetazoline, 3,4-methylenedioxy-N-methylamphetamine [39] or upon larger consumption of alcohol [35]. Mateo-Montoya and others demonstrated an increased incidence in patients with a positive test for *Helicobacter pylori*, the presence of which may also trigger extraintestinal pathologies including CSC (urease, which *Helicobacter pylori* produces, activates blood platelets, which in the region of the choroid may lead to vascular congestion and subsequently choroidal ischemia) [40,41]. Hypertension, obstructive sleep apnea, smoking, alcohol, antihistamines, and allergic respiratory disorders are further risk factors stated in the literature [42].

Although this concerns an acquired disorder, genetic predisposition plays an important role in the pathophysiology of CSC, as does genetic polymorphism [43]. A probable connection between the gene for complement factor H and CSC has been demonstrated by several studies independently of one another [44–46]. However, the precise mechanism of influence of factor H in the pathogenesis of CSC is still not known.

## PROGNOSIS

CSC may appear in 2 basic forms – acute and chronic. The designation of chronicity of the pathology has not been precisely defined by any authorities. Some authors define chronicity as persistent SRF for a period of 6 months [47], whereas recent clinical trials have inclined towards a duration of the disease for a minimum of 3 months [12]. In most cases of acute forms of CSC, spontaneous resorption of SRF takes place within 3 months of the onset of the pathology, with adjustment of visual functions with final central VA often of 0.8 and better (in 80–90% of cases) [48]. However, even despite the improvement of central VA, after the subsidence of the disease patients may complain of dyschromatopsia (impairment of color perception), reduced contrast sensitivity, metamorphopsia (perception of deformed image), central scotoma, and in rare cases night blindness. According to the results of the study conducted by Ooto et al., who examined the density of cones in the macular area in patients with resulting VA of 20/20 and better, even after the resorption of the SRF and upon preservation of the ellipsoid zone (EZ), there was a reduction in the density of cones in the originally affected region [49]. This data may explain the residual visual complaints even in patients with excellent resulting VA and complete anatomical adjustment. The determination of BCVA itself thus need not necessarily fully reflect the actual quality of visual functions in patients with CSC. CSC may lead to permanent damage to sight if the SRF is not absorbed, or if attacks are repeated and the condition progresses to the chronic stage. As many as 52% of patients recorded a recurrence of the pathology within 1 year of the

first attack [50]. Long-term detachment of the neuroretina leads to cell death of photoreceptors, progression of RPE atrophy, subretinal fibrosis, the development of secondary CNV or cystoid macular degeneration, and thereby to a permanent deterioration of visual functions with central VA of 0.1 and worse. The final clinical picture is presented by DRPE, above which SRF may, though need not necessarily, be present [23].

## PATHOPHYSIOLOGY OF THE DISEASE

The precise pathophysiology of the disease is not known in detail, and it is assumed that it incorporates a somewhat diverse etiology and mechanisms, which in their consequence lead to extensive abnormalities of choroid circulation and subsequent breach of the RPE [51]. Thanks to new imaging and examining techniques, a number of theories have emerged to explain the possible cause of the pathology; in their way each of them may contribute to explaining the onset and progression of the pathology at least in part. An insight into the issue of the pathophysiology of CSC and its dynamics is best provided by fluorescein and indocyanine green angiography. The anatomical relations of the eye in CSC are then best identified by OCT (especially in the case of enhanced depth imaging – EDI-OCT) and OCT-angiography – OCT-A).

### Choroidal dysfunction theory

The current understanding of the pathogenesis of CSC places the greatest emphasis on the role of the choroid. Gass believed that the focal increase in permeability of the choriocapillaris was the primary cause of damage to the RPE layer situated above it, leading to detachment of the RPE, serous detachment of the neuroretina and in approximately 10–15% of patients to the formation of serofibrinous subretinal exudates [1]. The increase in the permeability of the choroidal vascular bed is probably caused by stasis in the vessels of the choroid, ischemia or inflammation, which is attested to by increased fluorescence of the inner choroid, especially in the central part of the ICG angiogram [3,52]. Guyer et al. proposed a potential model of the pathogenesis of CSC based on ICG-videoangiography (ICG-V). The ICG angiogram detected dilation of the large choroidal blood vessels and multifocal areas of hyperfluorescence in practically all the choroidal layers. The authors recorded diffuse zones of hyperpermeability within the surrounding area of active leaking points, which were evident on ICG-V, but not upon FAG examination. As a result, they concluded that hyperpermeability was on the level of the choroid, which can be better examined with the aid of ICG, rather than on the level of the RPE, the stability of which is more visible on FAG. Choroidal hyperpermeability increases hydrostatic pressure in the choroidal space, which then further increases demands on the RPE layer; this leads to its detachment, weakening, defect and eventual decompensation. This is then followed by infiltration, thus

of the diffuse of fluid, electrolytes and proteins into the subretinal space, thereby causing detachment of the neurosensory part of the retina [53]. At the same time, breached cells of the RPE lose their capacity to pump fluid in a retrograde direction – thus from the subretinal space into the region of the choroid. RPE cells may in fact focally lose their polarity and actively pump fluid into the subretinal space [54]. This condition limits the absorption of SRF and is therefore decisive with regard to the size, shape or chronicity of serous detachment of the neuroretina and/or RPE. Spontaneous resorption of fluid may occur if the defect in the RPE heals, and if at the same time the function of the RPE is at least partially preserved. The cause of increased permeability is not entirely known, but it is assumed that stasis in the choroidal veins, choroidal ischemia or inflammation may play an important role [52,55,56]. In the study conducted by Pruntes and Flammer, dilated capillaries and draining venules in one or more choroidal lobules followed by a localized delay in arterial filling may explain the cause of damage to the RPE layer above these areas of increased choroidal permeability. These conclusions support the idea of local lobular choroidal inflammation or ischemic choroiditis [52]. Abnormal regulation of blood flow of the choroid may be the main mechanism leading to typical “pachychoroid” changes [57]. The primary role of the choroid is newly supported by findings on EDI-OCT, demonstrating an increased thickness of this layer in patients with CSC [4].

From the above it ensures that intensive exudation of the choroidal vessels in active CSC is caused primarily by breach of the vascular wall, abnormality or defect of the autoregulation of choroidal blood flow [58], and not the presence of CNV. There is strong evidence in favor of choroidal vasculopathy in the etiopathogenesis of CSC, though we still lack a precise delineation of the fundamental mechanism of origin of choroidal lesion.

### **RPE dysfunction theory**

RPE dysfunction occupies a significant role in the pathogenesis of CSC, and for this reason advocates of this theory prioritize defect on the level of the RPE as the primary cause of the onset of the pathology [59–61]. FAG in patients with active CSC detects one or more sources of leakage, causing serous detachment of the retinal pigment epithelium and/or neuroretina. The typical finding on FAG demonstrates fluid flowing into the subretinal space via a defect of tight connections between the cells of the retinal pigment epithelium. These focal leaking points through the RPE, which are typical of the acute form of CSC, were the first guidepost to determining the pathogenesis of the disease, and were considered the primary cause of accumulation of SRF [48]. Although it is rather the theory of choroidal dysfunction that is more widely recognized today, the RPE plays a fundamental role in the course of the pathology. Unlike the acute form of CSC, in which damage to one or more RPE cells occurs and serous detachment regresses spontaneously in most cases upon the expiration of these sources of leakage, in

the chronic form, represented by diffuse disintegration of the RPE (which is clearly shown on autofluorescence and FAG), there is a widespread disruption of the RPE as the outer blood-ocular barrier and a defect of the capacity to pump fluid in a retino-choroidal direction, which leads to a chronic accumulation of fluid in the subretinal space and further damage to the RPE cells [23].

### **Combined choroid and RPE dysfunction theory**

In probability, both theories contribute to explaining the cause and course of the pathology, namely increased permeability of choroidal vessels, elevation of hydrostatic pressure in the choroid and impaired function of the RPE [23].

### **Role of corticoids in the development of CSC**

CSC induced by corticosteroids was first described in 1984 [62]. Since that time a series of clinical and experimental studies have been published, demonstrating that endogenous and exogenous corticosteroids contribute to the development of CSC [31,63–66]. Jampol et al. stated in their publication that corticosteroids might increase the sensitivity of choroidal blood vessels or RPE cells to the effect of endogenous catecholamines [67]. CSC is also more often identified in patients with a higher level of endogenous corticoids (Cushing's syndrome, pregnancy, stress), similarly as in the case of patients with hypercortisolism resulting from the treatment of ocular (uveitis, scleritis, optic neuritis) or systemic pathologies (bronchial asthma, hepatitis, allergic rhinosinusitis) [31–33,68–71]. Evidence exists attesting to the influence of glucocorticoids on the transcription and expression of adrenergic receptors, indicating the long-term effect of corticoids on the genome level, mediated by intracellular receptors. On the cellular level, the influence of glucocorticoids leads to increased expression of beta-adrenergic receptors [72]. On the molecular level, the same authors have demonstrated the effect of glucocorticoids on the expression of beta-adrenergic receptors through the presence of a higher level of intracellular receptor mRNA. Similarly, Sakaue also determined that expression and increase of the quantity of alpha-1 $\beta$ -adrenergic receptors on the surface of the cells is induced by glucocorticoids [73]. The influence of expression on the genome level is not immediate, and is due to long-term exposure to higher levels of corticosteroids. The effect of corticoids on the non-genome level is prompt, and is determined by their direct interaction with the glucocorticoid receptors already present in the cell membranes; these incorporate ion channels or receptors for neurotransmitters [67,74]. Their activation causes damage to the endothelial cells of the choriocapillaris, and therefore its greater permeability and the degeneration of the RPE layer situated above it [37,75].

### **Pathophysiology of loss of VA in CSC**

Weakening of the retina in the fovea, cystoid macular degeneration, and damage to the photoreceptors of the macular area are considered reasons for the de-

terioration of VA in CSC [76,77]. Cystoid macular degeneration was first described by Iida as a cystoid intraretinal cavity without evidence of leakage on FAG [76]. A duration of the pathology of at least 5 years and subretinal fibrosis are considered the main risk factors [77]. The key factor regarding the resulting visual functions is the preservation of the outer retinal layers. Loss of photoreceptors and RPE cells upon a background of long-term detachment of the neuroretina leads to a significant deterioration of visual functions [78].

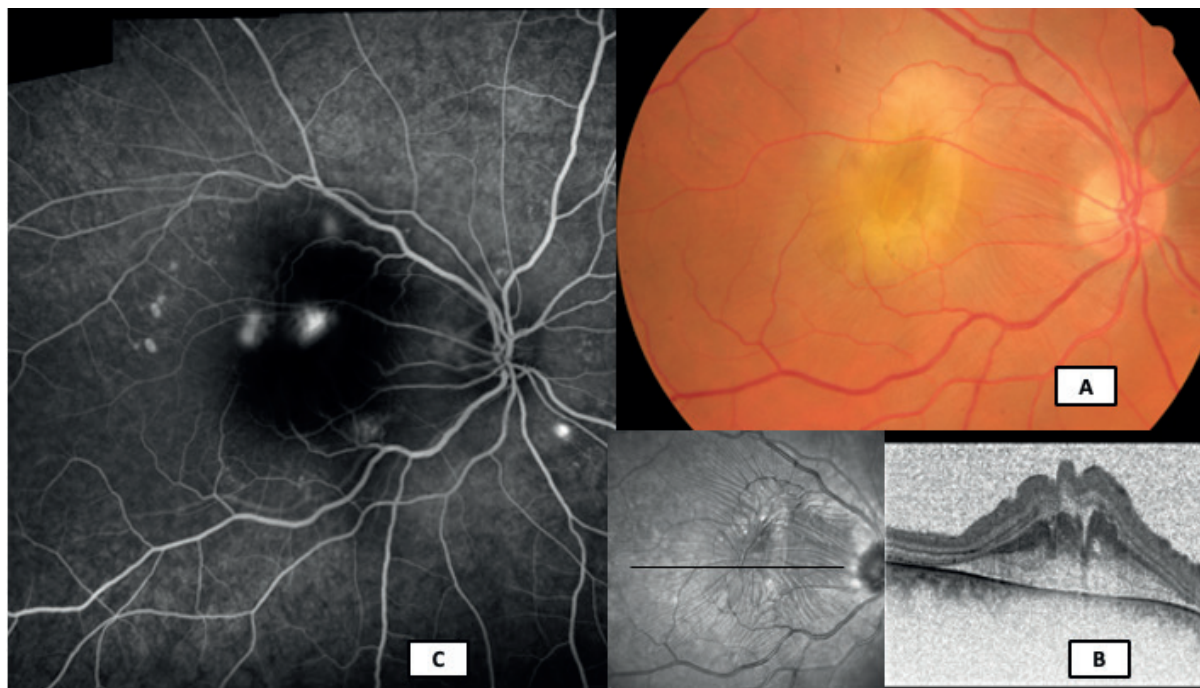
## CLASSIFICATION OF CSC

The aim of any classification of a pathology is to divide the broad range of manifestations of the pathology into subcategories, which assist us in determining its probable development, prognosis, and the most appropriate plan of treatment. To date several classifications of CSC have been published, but none of them have fully contained all possible manifestations of the disease. In very simple terms, up to now the pathology has been divided into the acute and chronic forms [23]. Daruich et al. recently proposed a new classification, which incorporates the individual (and rare) manifestations of CSC [79], and this classification is now generally recognized [80]:

**1. Acute CSC:** The most common type, predominantly affecting younger patients and causing acute localized detachment of the RPE and/or neuroretina with mild to medium deterioration of visual

functions. On FAG we find one or more sources of dye leakage. In 95% of cases, spontaneous resorption of the SRF takes place, as well as adjustment of visual functions, though in certain patients a disorder of color perception may persist [81].

- 2. Persistent CSC:** In a certain percentage of cases, SRF persists for longer than 3 months. As a rule, for these patients we indicate new FAG/ICG in order to identify the locations of leakage. The result of angiography may be hyperfluorescence in the original location, a new source of leakage or no demonstrated activity. If a new source of fluorescein leakage is demonstrated, the pathology is considered persistent.
- 3. Recurrent CSC:** Defined as the repeated presence of SRF following its documented complete reabsorption, occurring in 50% of patients in the first year of the disease [82]. On FAG we may find the same source of leakage or a de novo appearing hot-spot.
- 4. Chronic CSC:** Serous elevation of the RPE and/or neuroretina persisting for longer than 3 months upon a background of chronic changes and alteration of the function of the RPE. Long-term detachment of the neurosensory retina leads to a further worsening of the RPE alteration, the occurrence of typical widespread atrophic traces of the RPE and atrophy of the photoreceptors [83]. In its advanced stage, this variant is also referred



**Figure 1.** Color fundus photo, optical coherence tomography scan and fluorescein angiography (Visucam Zeiss, Heidelberg Spectralis, Myslík Manethová) in a 38-year-old patient with an atypical – bullous – form of central serous chorioretinopathy: (A) color image of excessive yellowish subretinal fibrin exudation in center of the macula with radial retinal folds, (B) transfoveal linear scan with a subretinal hyperreflective mass and significant decompaction of the inner retinal layers, (C) wide-field fluorescein angiography with multiple active hot-spots of varying intensity